



Lung ultrasound in Internal Medicine: Clinical applications and clinical cases

Luna Gargani

Cardiology Department
Institute of Clinical Physiology
National Council of Research, Pisa, Italy



Gent, 22nd November 2014

Clinical applications

1. Heart Failure

- Diagnosis
- Follow-up
- Prognosis

2. ARDS

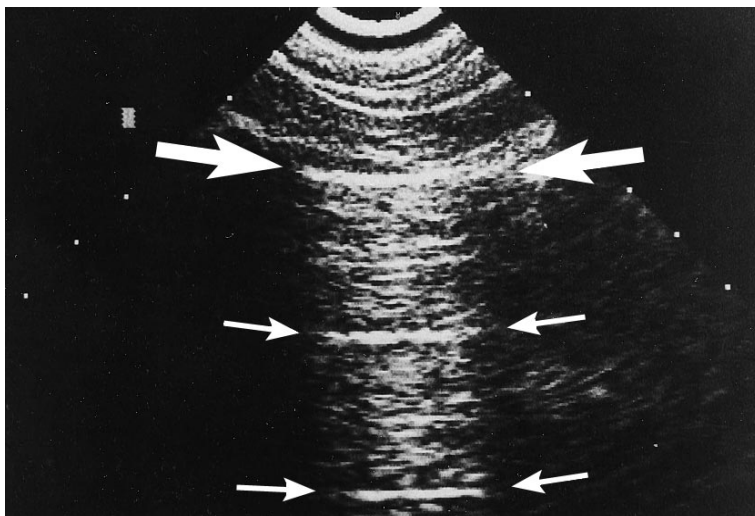
3. Pneumonia (consolidations)

4. Dialysis

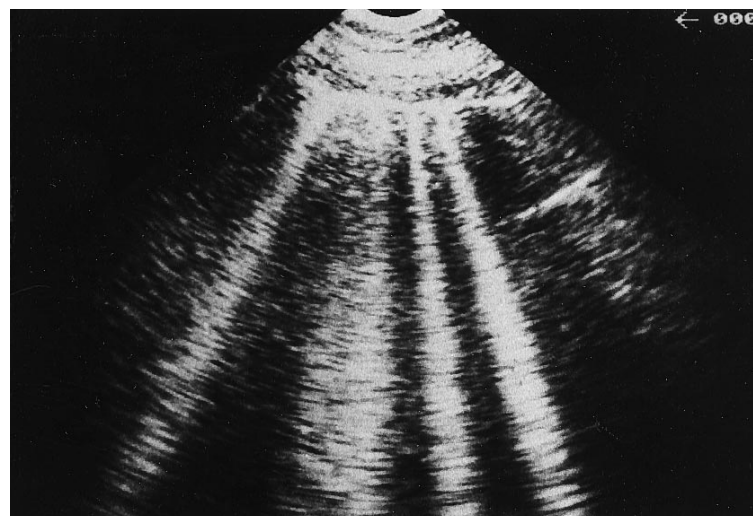
5. Pulmonary fibrosis

D. Lichtenstein
G. Mezière

A lung ultrasound sign allowing bedside distinction between pulmonary edema and COPD: the comet-tail artifact



Exacerbation of COPD

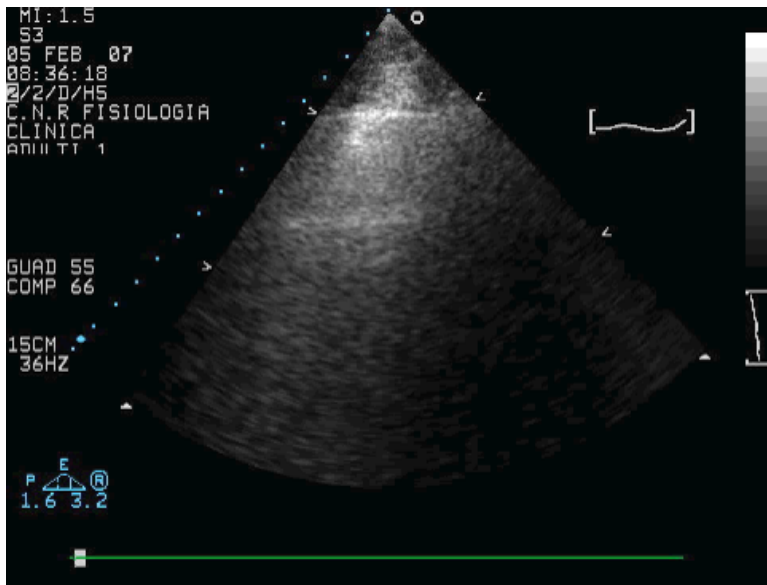


Acute pulmonary oedema

D. Lichtenstein
G. Mezière

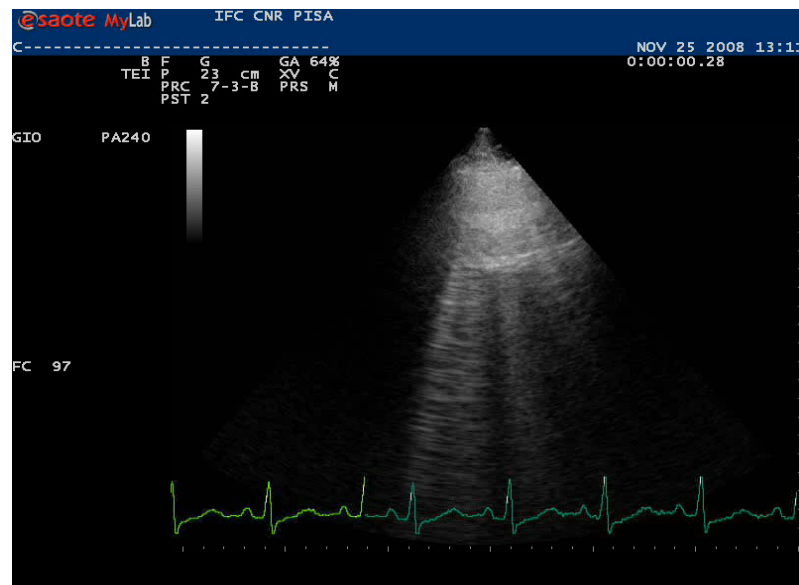
A lung ultrasound sign allowing bedside distinction between pulmonary edema and COPD: the comet-tail artifact

No B-lines



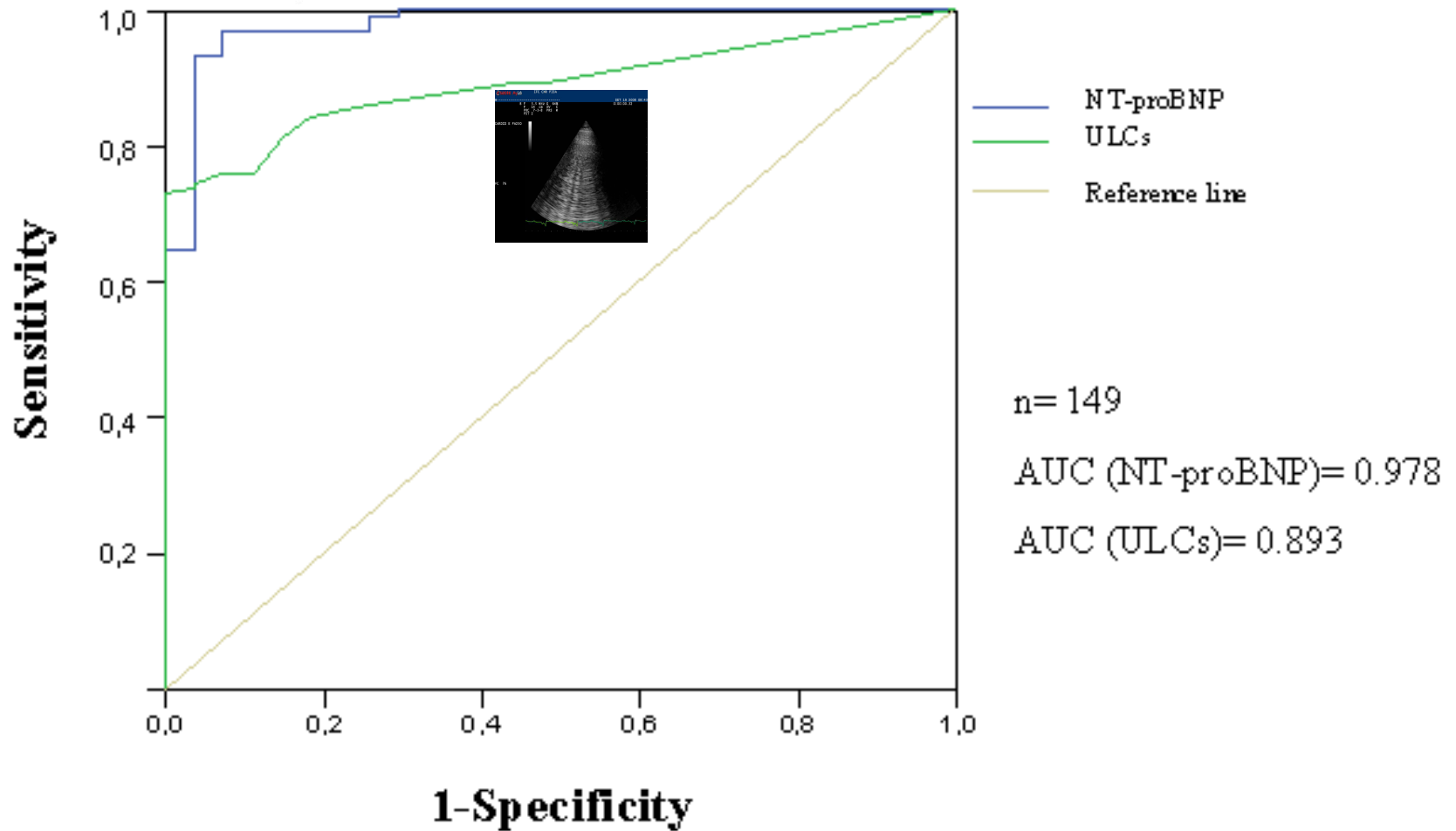
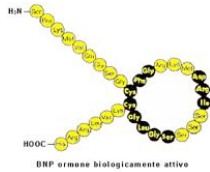
Exacerbation of COPD

Multiple B-lines



Acute pulmonary oedema

B-lines and natriuretics peptides



B-lines at the emergency department

Emergency Thoracic Ultrasound in the Differentiation of the Etiology of Shortness of Breath (ETUDES): Sonographic B-lines and N-terminal Pro-brain-type Natriuretic Peptide in Diagnosing Congestive Heart Failure

Andrew S. Liteplo, MD, RDMS, Keith A. Marill, MD, Tomas Villen, MD, Robert M. Miller, MD, Alice F. Murray, MBChB, Peter E. Croft, BS, Roberta Capp, MD, and Vicki E. Noble, MD, RDMS



RESEARCH

Open Access

Combination of lung ultrasound (a comet-tail sign) and N-terminal pro-brain natriuretic peptide in differentiating acute heart failure from chronic obstructive pulmonary disease and asthma as cause of acute dyspnea in prehospital emergency setting

Gregor Prosen^{1,2}, Petra Klemen^{1,2,3}, Matej Strnad^{1,2} and Štefek Grmec^{1,2,3,4*}

Intern Emerg Med
DOI 10.1007/s11739-011-0709-1

EM - ORIGINAL

Diagnostic accuracy and reproducibility of pleural and lung ultrasound in discriminating cardiogenic causes of acute dyspnea in the Emergency Department

Gian Alfonso Cibinel · Giovanna Casoli · Fabrizio Elia ·
Monica Padoan · Emanuele Pivetta · Enrico Lupia ·
Alberto Goffi

Emergency echocardiography: the European Association of Cardiovascular Imaging recommendations

Aleksandar N. Neskovic^{1*}, Andreas Hagendorff², Patrizio Lancellotti³, Fabio Guarracino⁴, Albert Varga⁵, Bernard Cosyns⁶, Frank A. Flachskampf⁷, Bogdan A. Popescu⁸, Luna Gargani⁹, Jose Luis Zamorano¹⁰, and Luigi P. Badano¹¹, on behalf of the European Association of Cardiovascular Imaging[†]

Lung ultrasound examination

In recent years, lung ultrasound (LUS) has been proposed as a useful point-of-care tool in emergency.²⁵

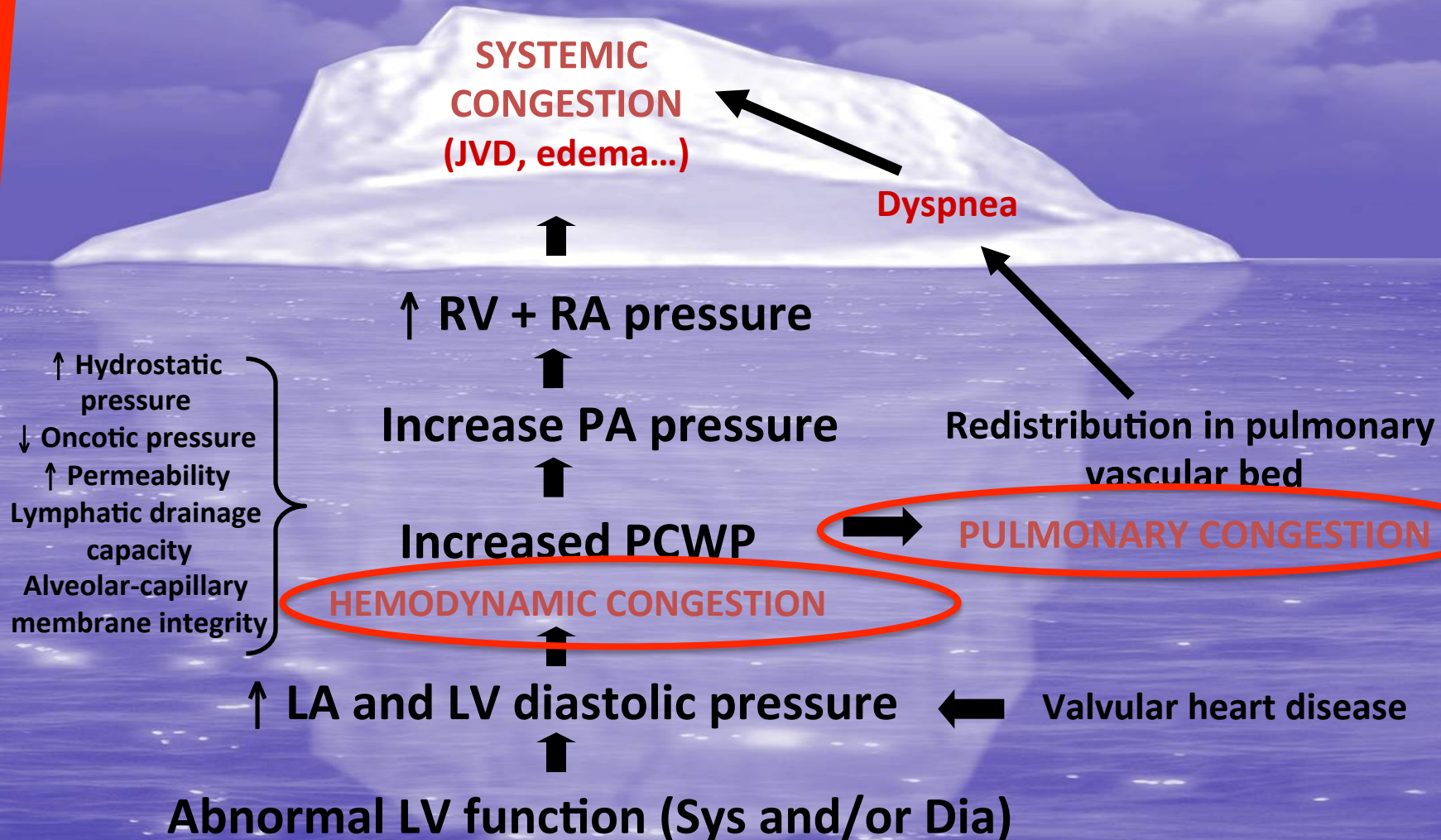
The LUS examination can be performed with any commercially available 2-D scanner, including pocket-size devices, by using a cardiac, convex or microconvex transducer, with the patient in the near-supine, supine, sitting, or even standing position.

In addition to the detection of pleural effusion, LUS may help in the diagnosis of acute dyspnoea, allowing the differential identification of pneumothorax, pulmonary consolidations, acute respiratory distress syndrome, and cardiogenic pulmonary oedema.²⁵

The absence of multiple bilateral B-lines, a sign of increased extravascular lung water, excludes cardiogenic pulmonary oedema with a negative predictive value close to 100%.²⁶

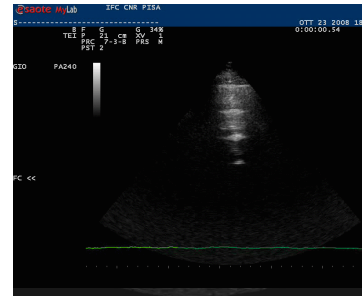
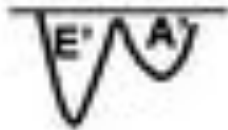The Congestion Iceberg in Heart Failure

S
Y
M
P
T
O
M
S



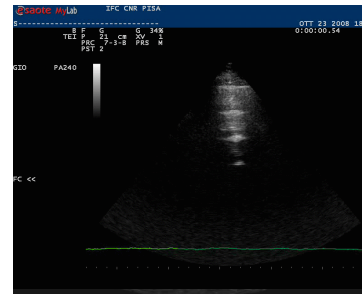
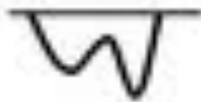
Hemodynamic vs pulmonary congestion

normal



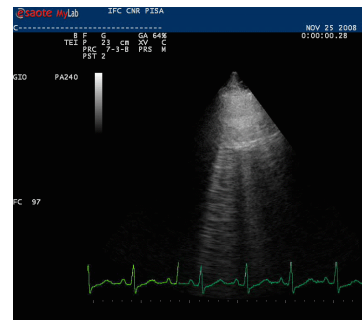
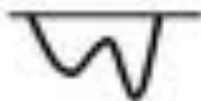
no congestion

elevated



hemodynamic
congestion

elevated



pulmonary
congestion

Clinical applications

1. Heart Failure

- Diagnosis
- Follow-up
- Prognosis

2. ARDS

3. Pneumonia (consolidations)

4. Dialysis

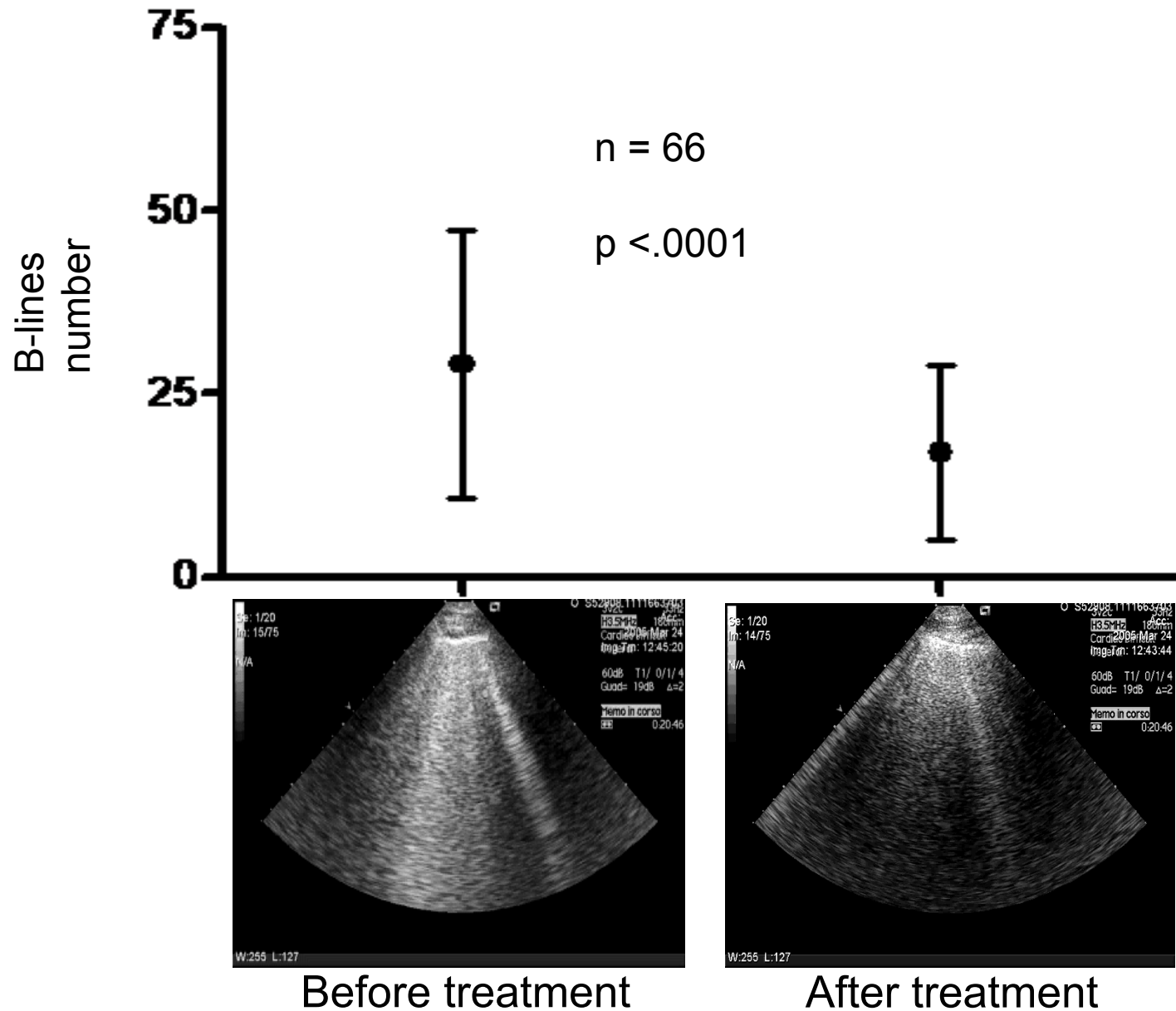
5. Pulmonary fibrosis

Acute heart failure

Table 4 Positive ultrasound lung scans in the 11 individualizable thoracic areas at admission (phase 1) and control (phase 2) in 70 patients admitted for ADHF

Thoracic area	Phase 1 ^a	Phase 2 ^a	<i>P</i> (<i>W</i>)
Anterior superior right	51 (73%)	3 (4.3%)	<.001
Anterior medium right	54 (77%)	2 (2.9%)	<.001
Anterior basal right	65 (93%)	4 (5.7%)	<.001
Lateral superior right	64 (91%)	5 (7.1%)	<.001
Lateral medium right	67 (96%)	10 (14%)	<.001
Lateral basal right	68 (97%)	21 (30%)	<.001
Anterior superior left	52 (74%)	6 (8.6%)	<.001
Anterior medium left	58 (83%)	6 (8.6%)	<.001
Lateral superior left	63 (90%)	6 (8.6%)	<.001
Lateral medium left	70 (100%)	11 (16%)	<.001
Lateral basal left	70 (100%)	20 (29%)	<.001

Furosemide stress test



Clinical applications

1. Heart Failure

- Diagnosis
- Follow-up
- Prognosis

2. ARDS

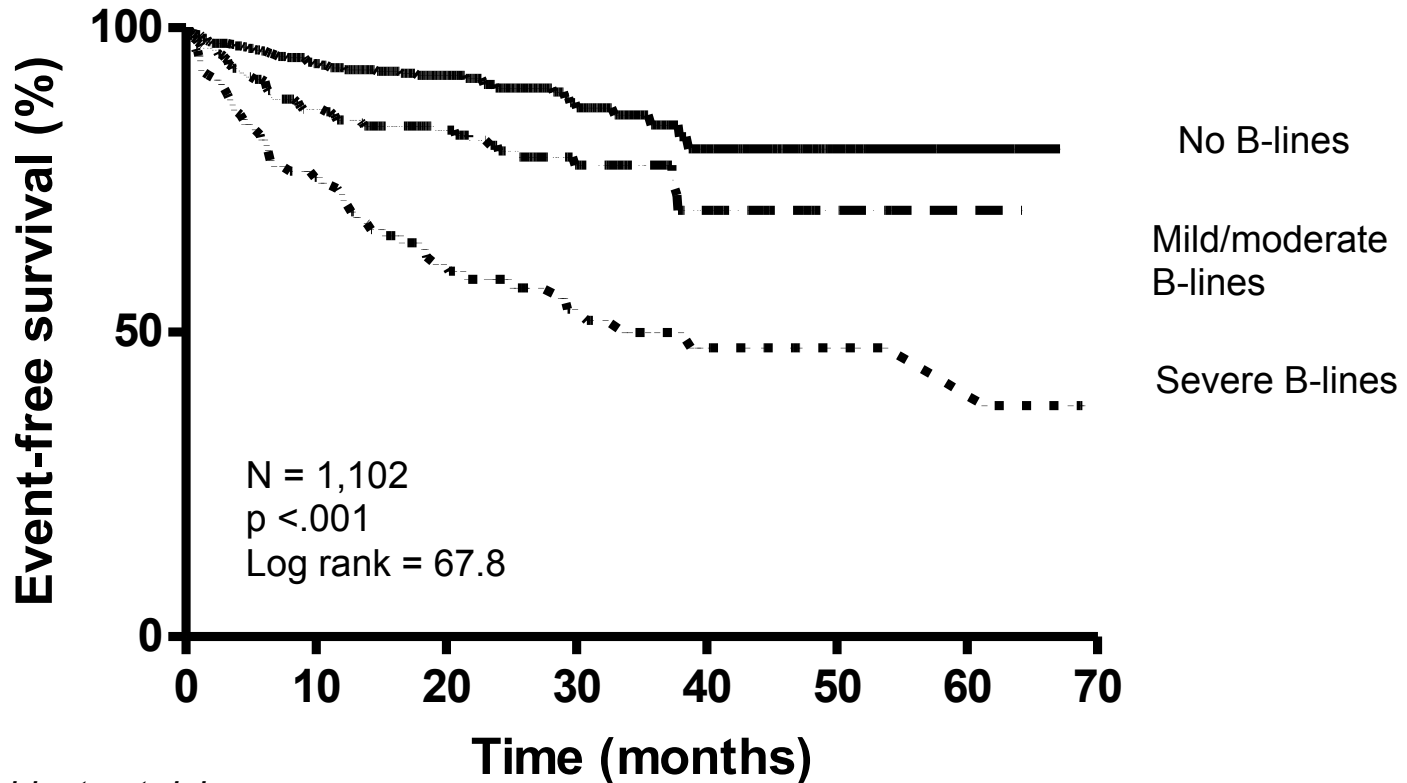
3. Pneumonia (consolidations)

4. Dialysis

5. Pulmonary fibrosis

Prognosis in cardiac patients

206 events (death, AMI, decompensated heart failure)



Subjects at risk

—	616	483	462	437
- -	342	291	267	249
· · · ·	144	117	106	96

Clinical applications

1. Heart Failure

- Diagnosis
- Follow-up
- Prognosis

2. ARDS

3. Pneumonia (consolidations)

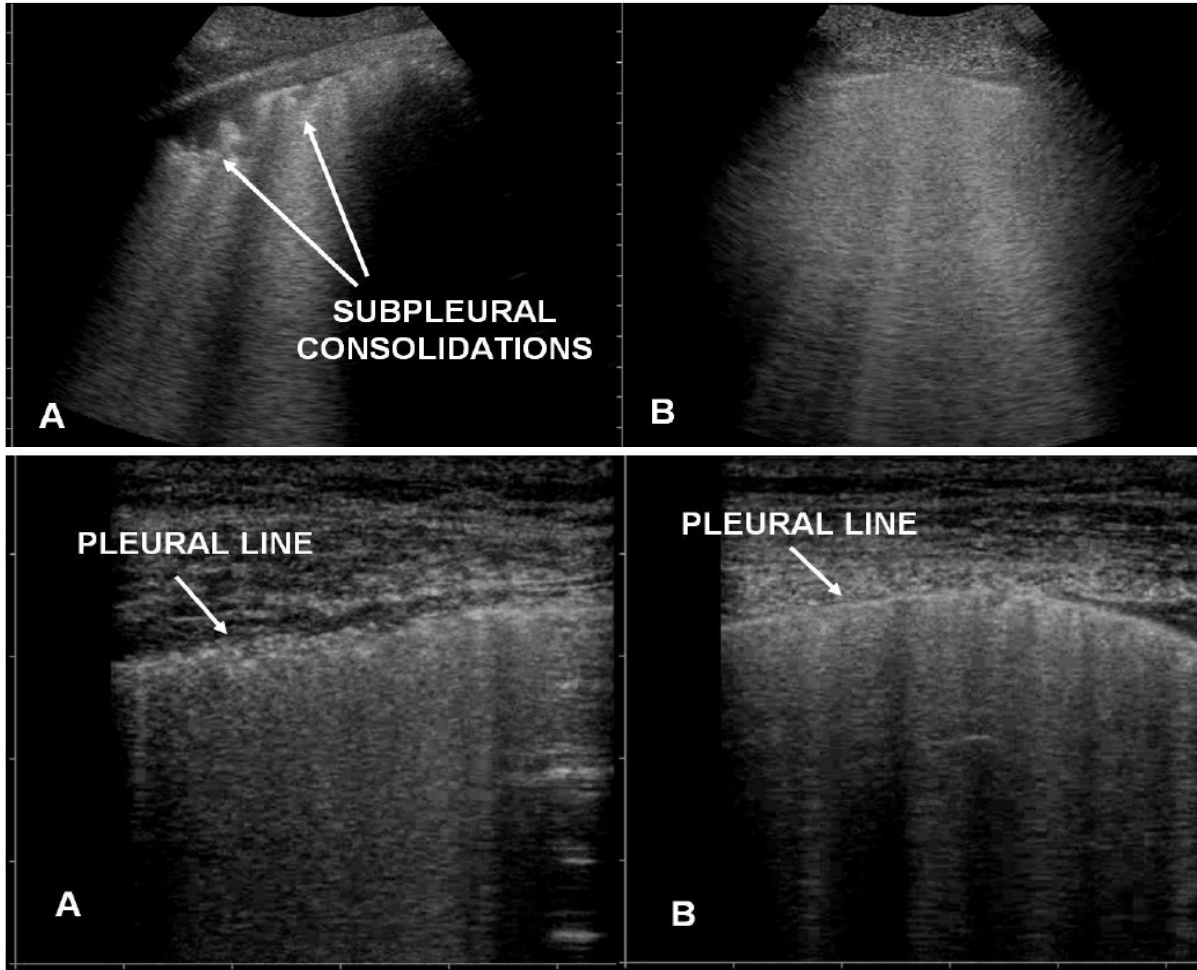
4. Dialysis

5. Pulmonary fibrosis

Cardiogenic edema vs ARDS

SUB-PLEURAL ALTERATIONS

ARDS

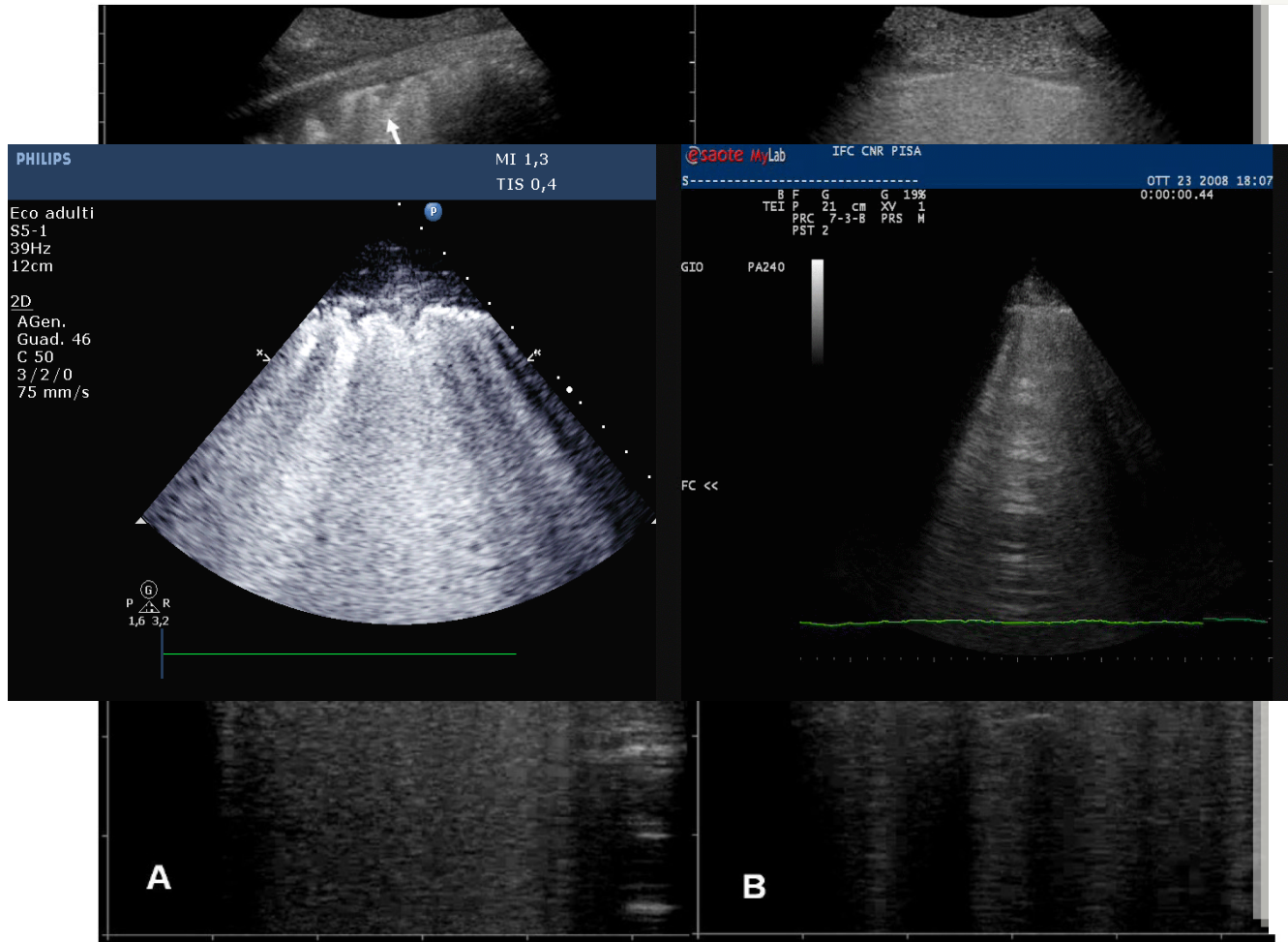


Cardiogenic
pulmonary
edema

Cardiogenic edema vs ARDS

SUB-PLEURAL ALTERATIONS

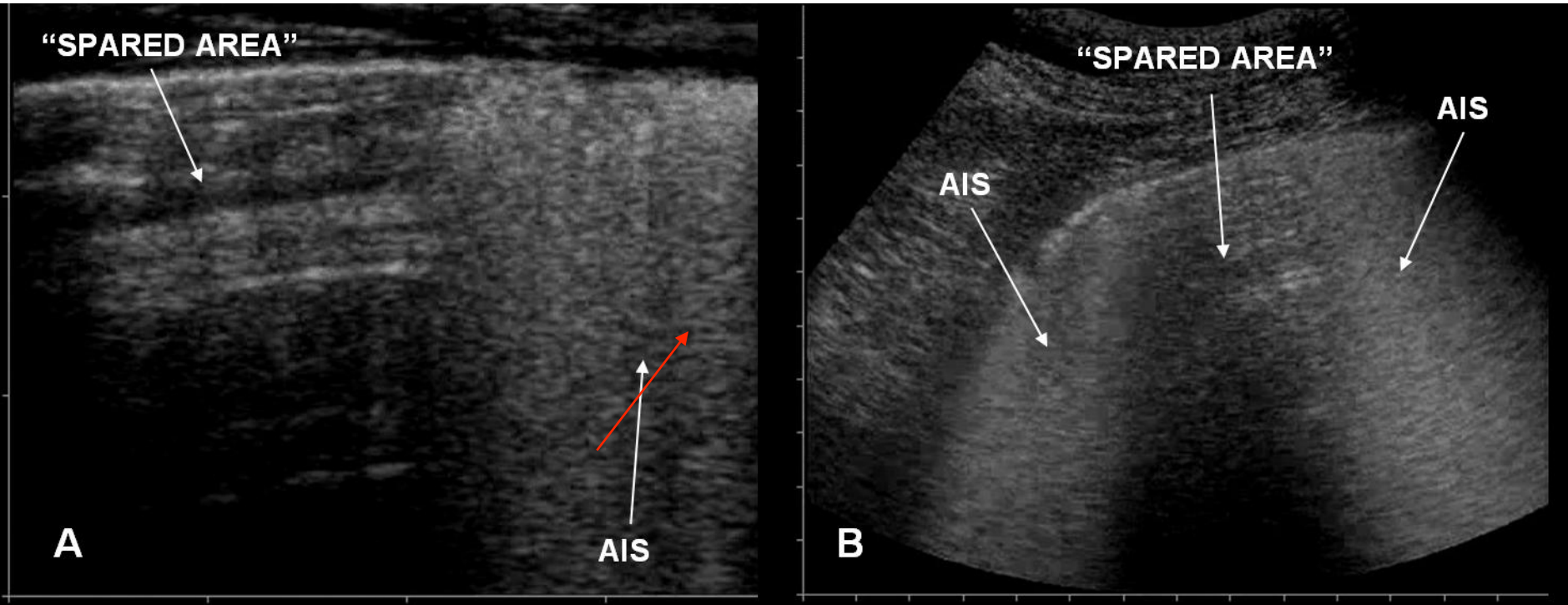
ARDS



Cardiogenic
pulmonary
edema

ARDS

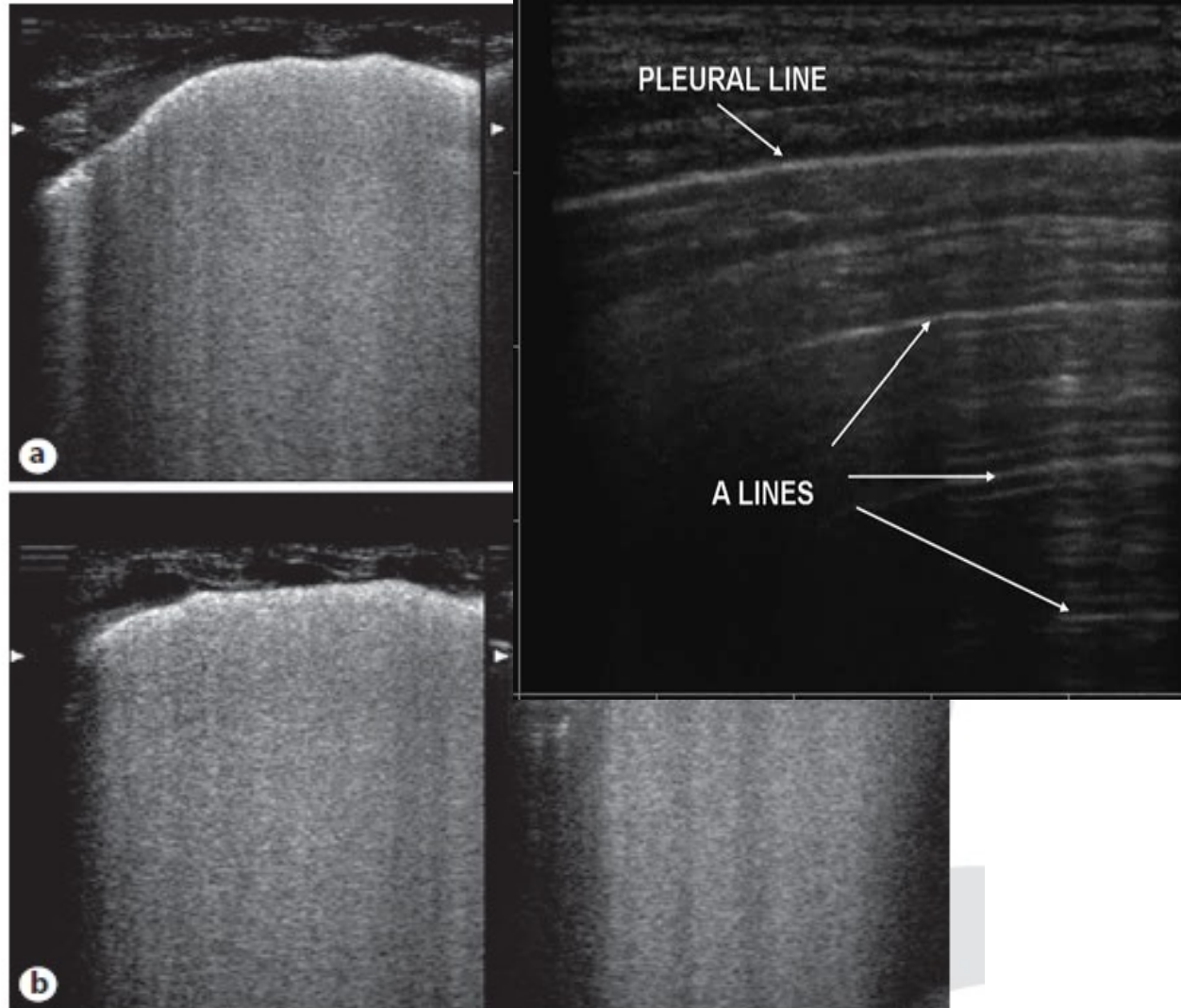
SPARED AREAS



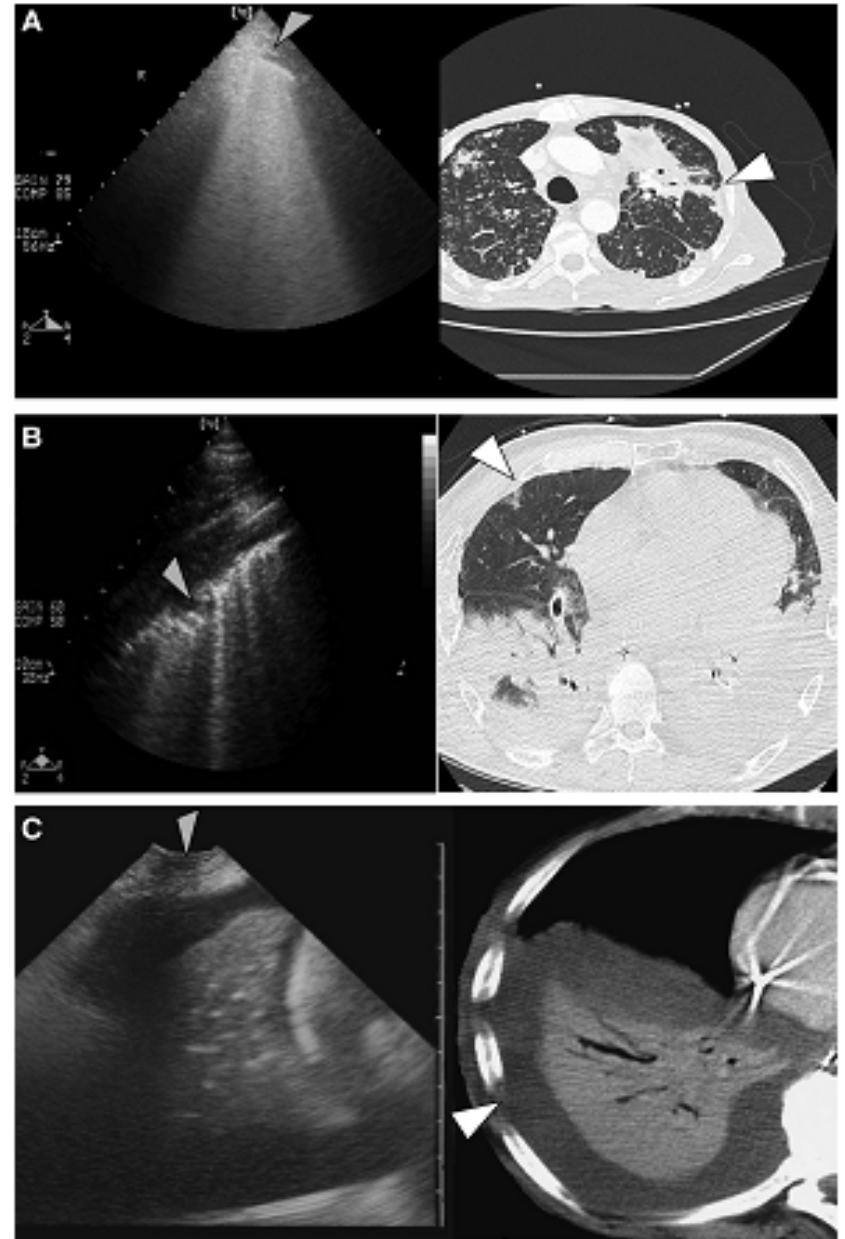
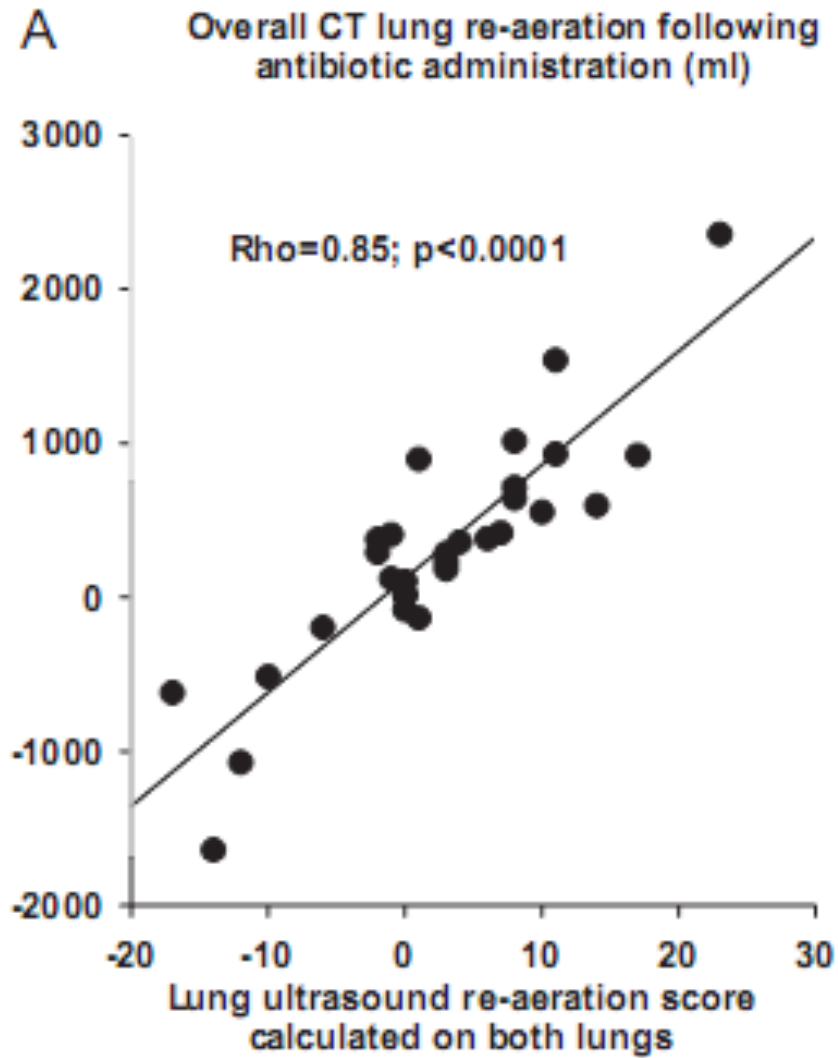
Hyaline membrane disease: neonates



WHITE LUNGS



Recruitment



Clinical applications

1. Heart Failure

- Diagnosis
- Follow-up
- Prognosis

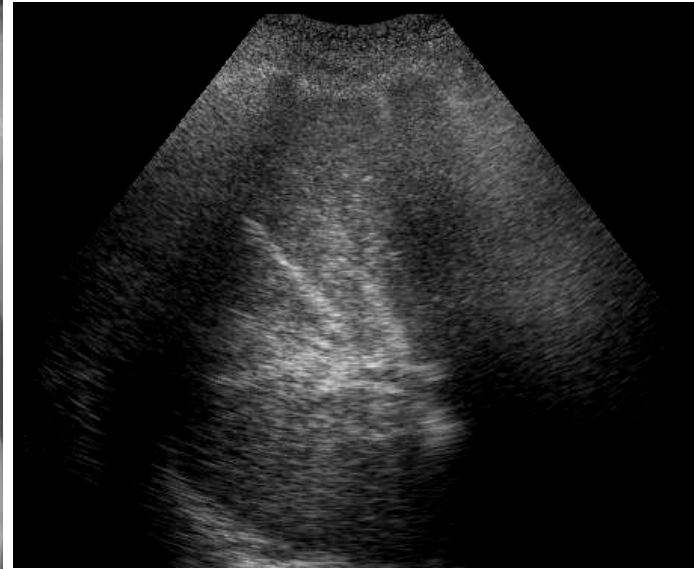
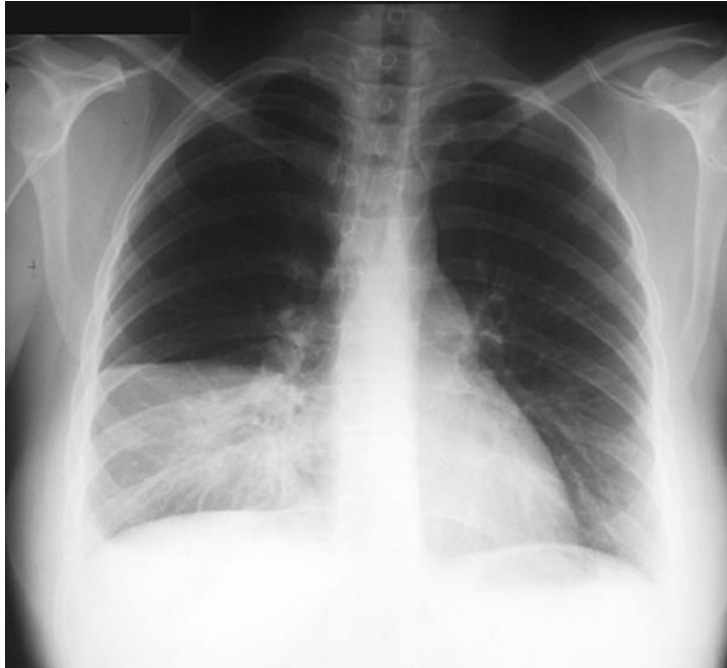2. ARDS

3. Pneumonia (consolidations)

4. Dialysis

5. Pulmonary fibrosis

Pneumonia



International Evidenced-based Recommendations for Point-of-Care Lung Ultrasound

Endorsed by the World Interactive Network Focused on Critical Ultrasound (WINFOCUS)

Writing Committee:

Giovanni Volpicelli (Chairperson)*, Daniel Lichtenstein, Gebhard Mathis, Andrew Kirkpatrick, Luna Gargani, Vicki Noble, Gino Soldati, Roberto Copetti, Belaid Bouhemad, Angelika Reissig.



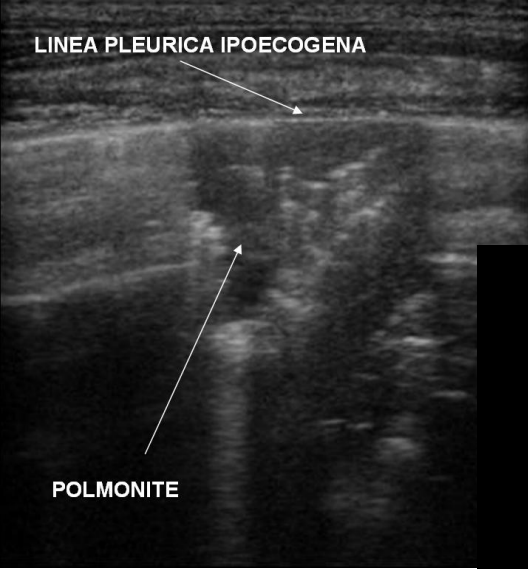Lung consolidation

Signs and clinical implications

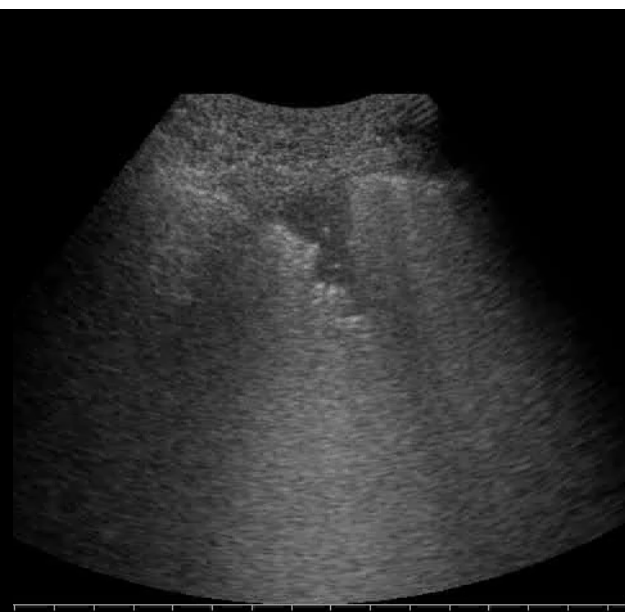
B-D3-S1 (strong: level C) (this statement combines statements P-D3-S4 and P-D3-S5)

- The sonographic sign of lung consolidation is a subpleural echo-poor region or one with tissue-like echotexture.

LINEA PLEURICA IPOECOGENA

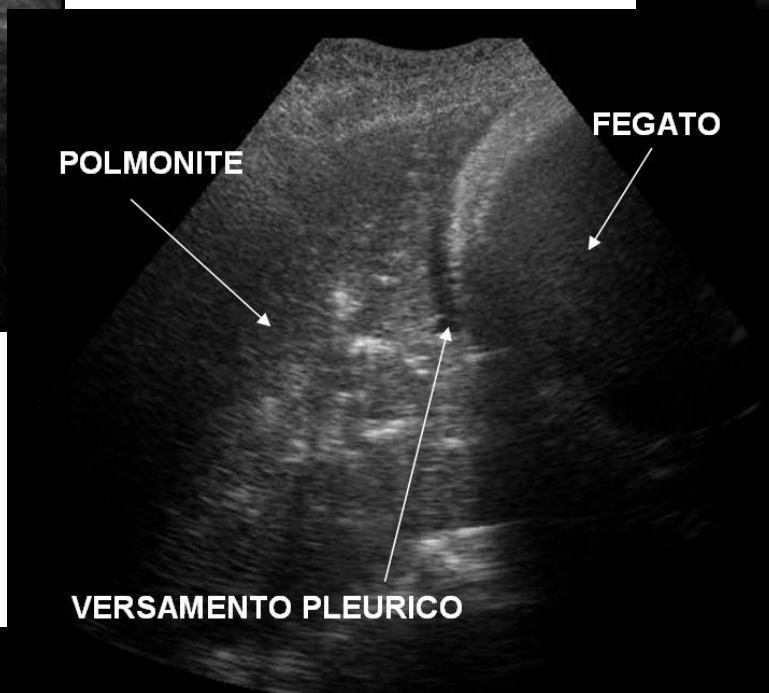


3.5 MHz
D 13 cm
PRF -

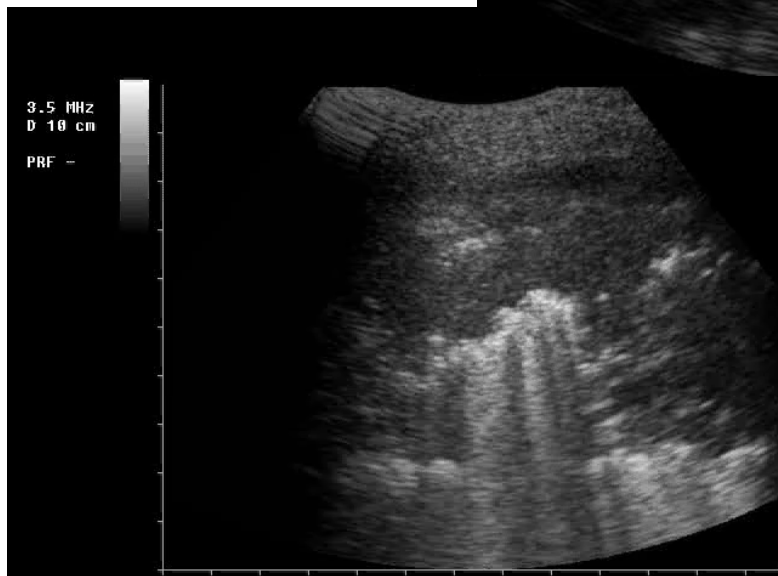


POLMONITE

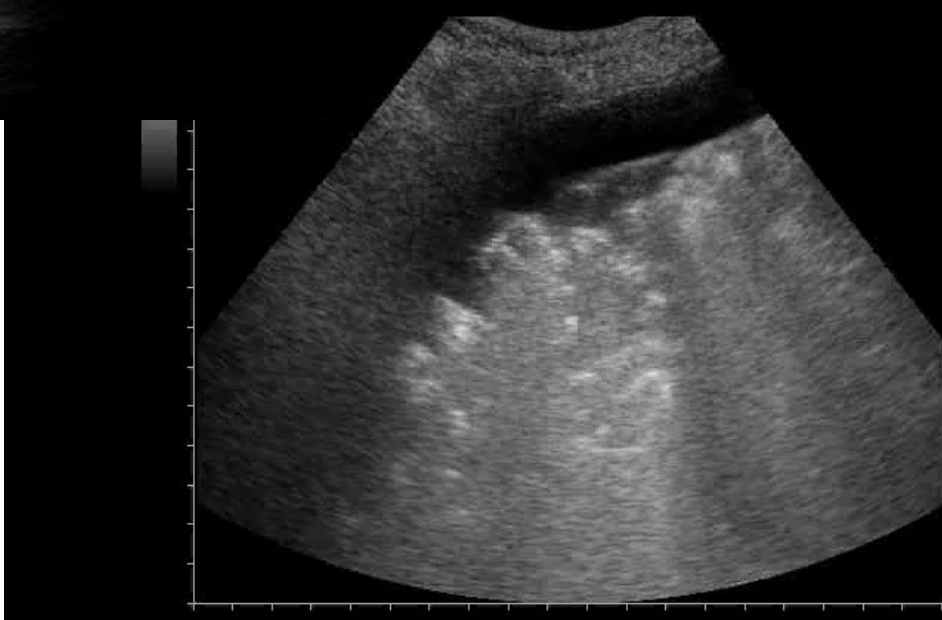FEGATO



3.5 MHz
D 10 cm
PRF -



3.5 MHz
D 10 cm
PRF -




International Evidenced-based Recommendations for Point-of-Care Lung Ultrasound

Endorsed by the World Interactive Network Focused on Critical Ultrasound (WINFOCUS)

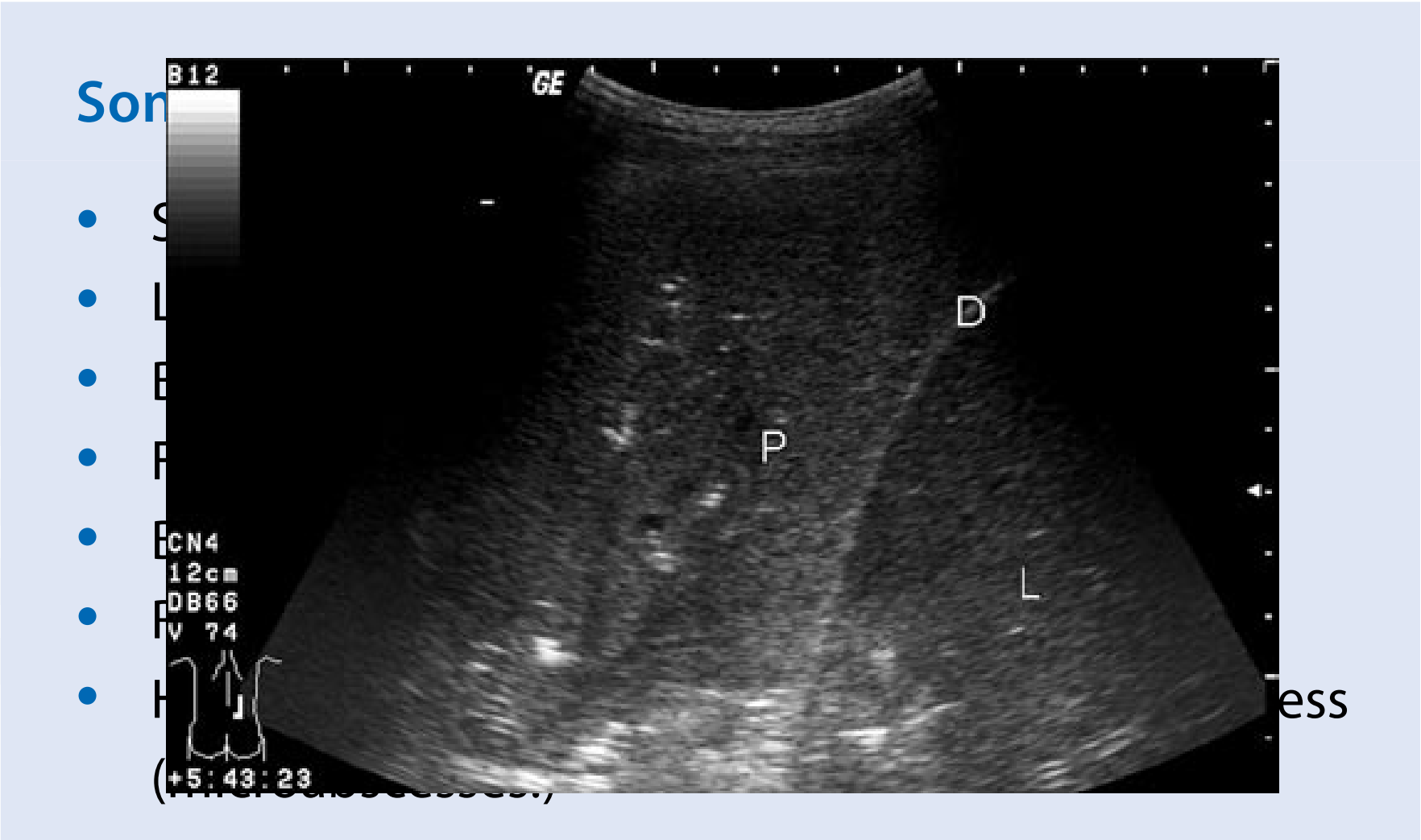
Writing Committee:

Giovanni Volpicelli (Chairperson)*, Daniel Lichtenstein, Gebhard Mathis, Andrew Kirkpatrick, Luna Gargani, Vicki Noble, Gino Soldati, Roberto Copetti, Belaid Bouhemad, Angelika Reissig.

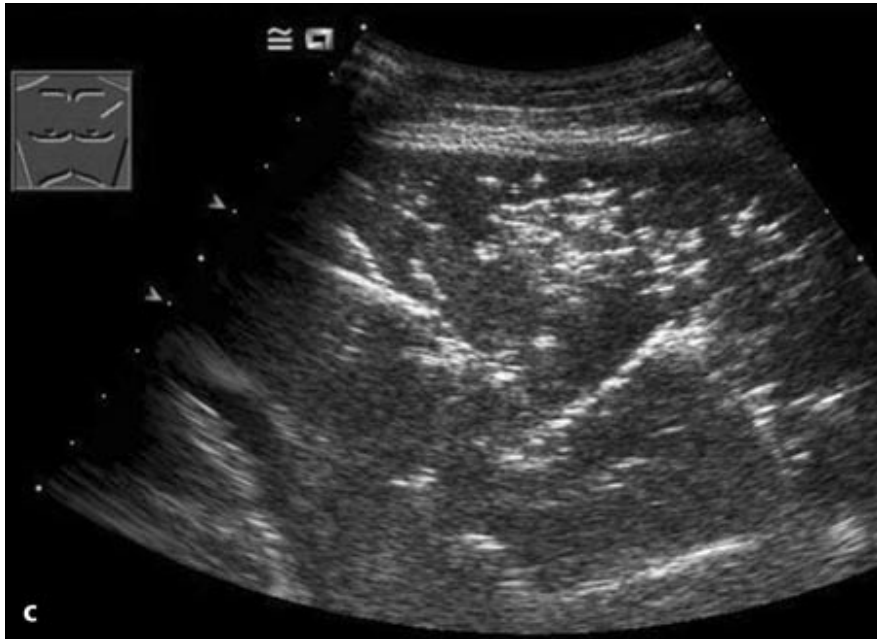

- In the evaluation of lung consolidation, the sonographic technique should commence with the examination of areas of interest (if present, e.g., area of pain) then progress to the entire lung, as needed.

Pneumonia



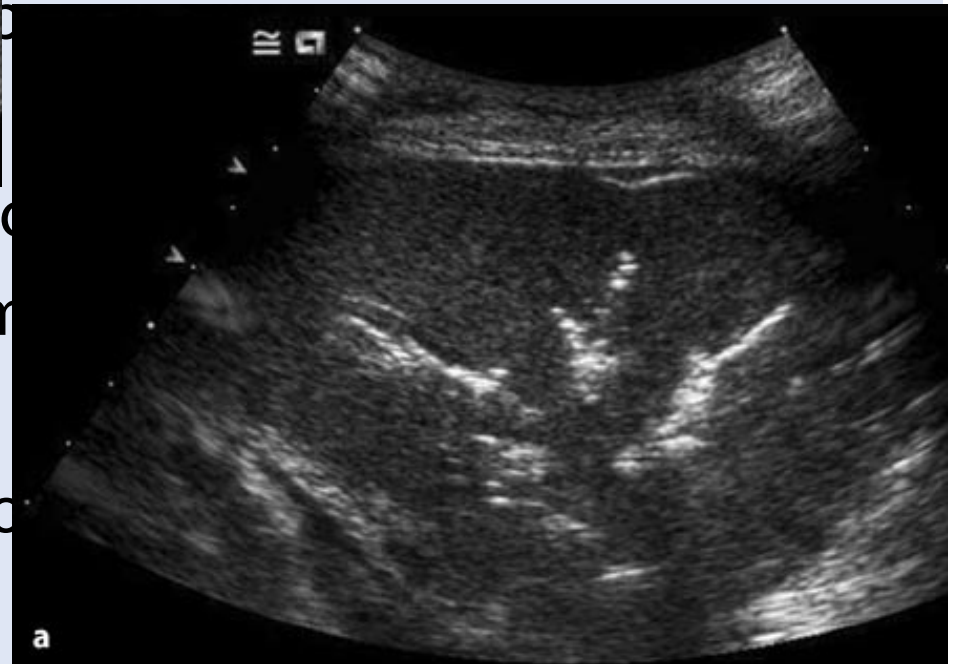Pneumonia



Pneumonia:

in the early stage

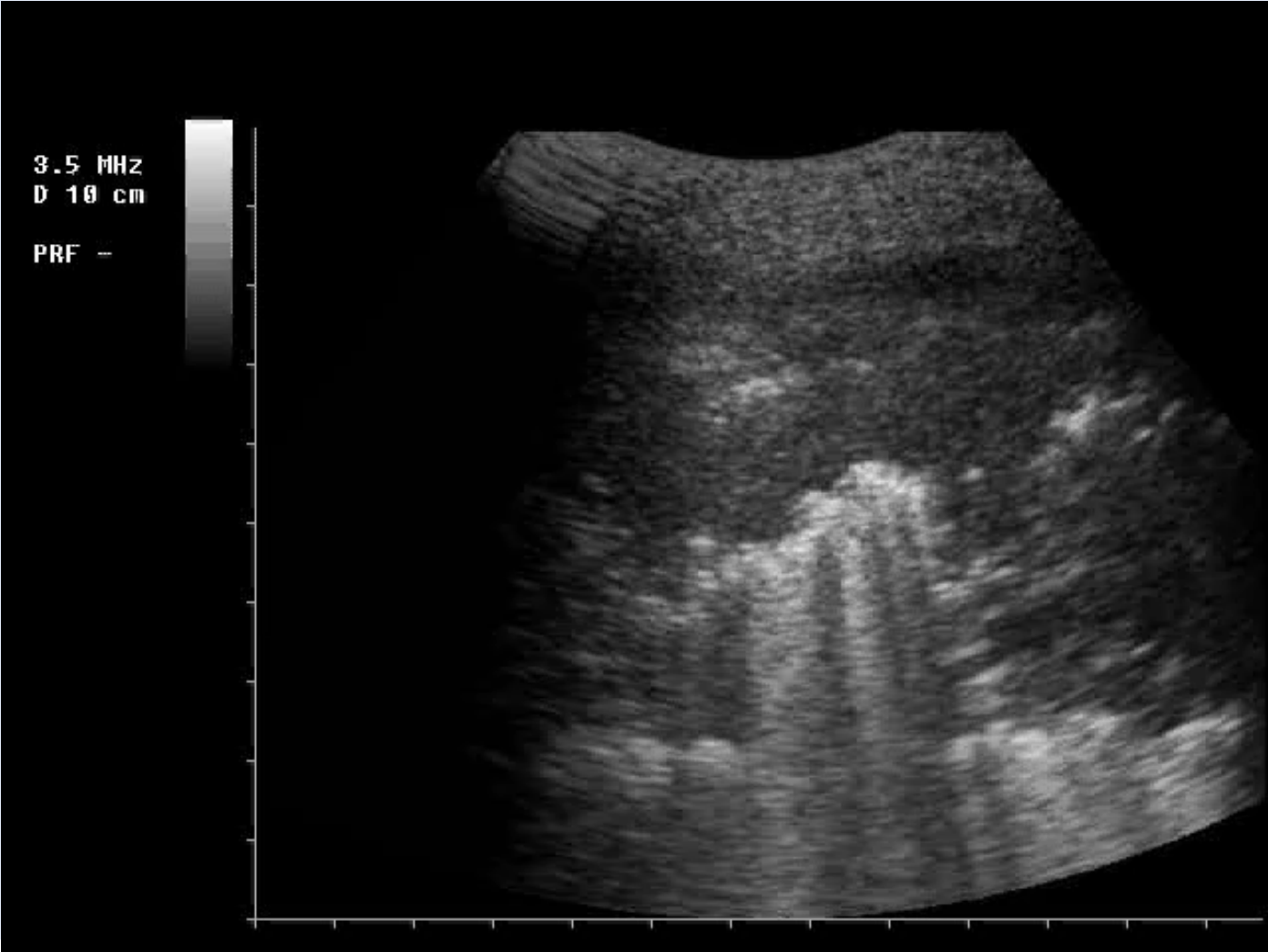
- Fluid bronchogram (pneumonia)
- Blurred and serrated margins
- Reverberation echoes
- Hypoechoic to anechoic areas (microabscesses!)



Pneumonia

So

-
-
-
-
-
-
-



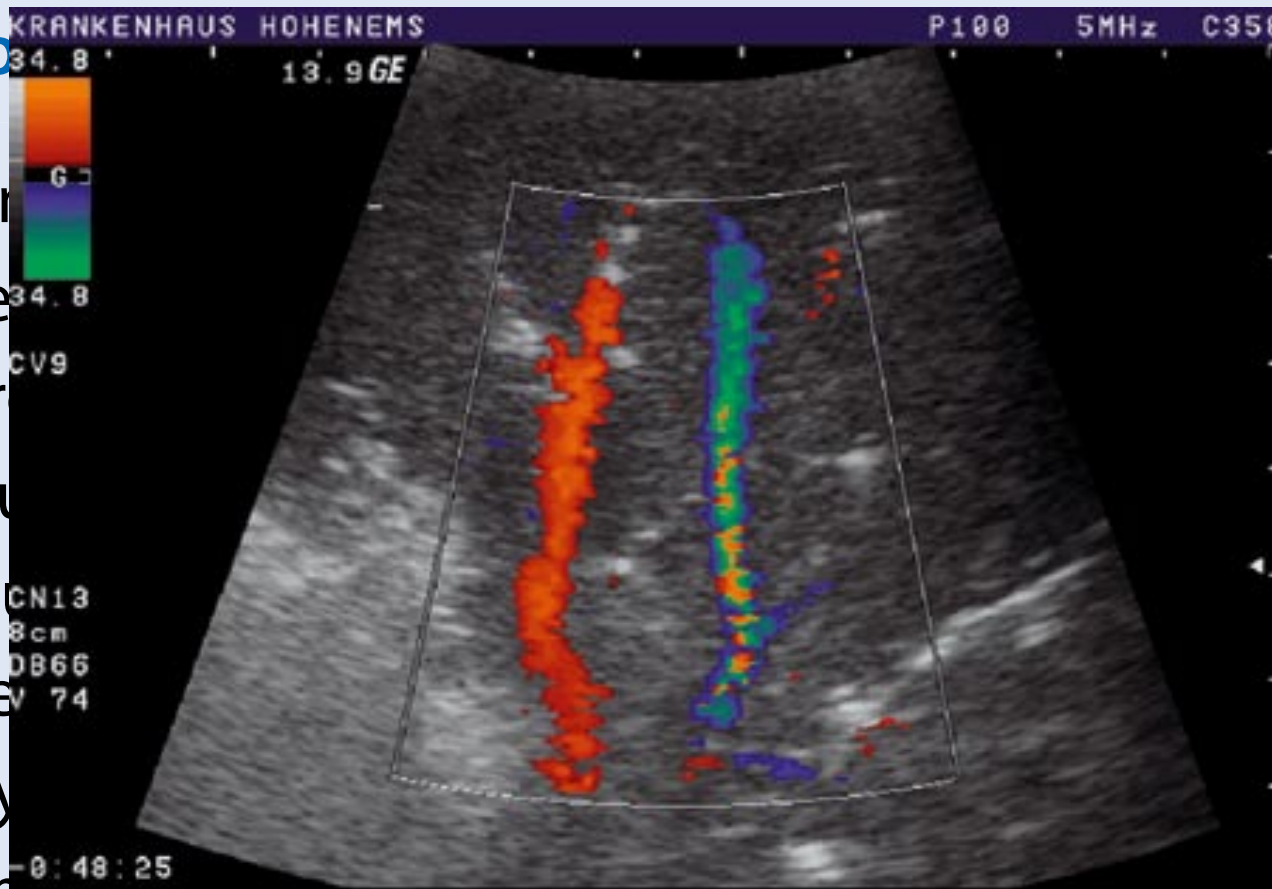cess

Pneumonia

Sono

- Sin
- Le
- Br
- Fl
- Bl
- Re
- Hy

(microabscesses?)



abscess

International Evidenced-based Recommendations for Point-of-Care Lung Ultrasound

Endorsed by the World Interactive Network Focused on Critical Ultrasound (WINFOCUS)

Writing Committee:

Giovanni Volpicelli (Chairperson)*, Daniel Lichtenstein, Gebhard Mathis, Andrew Kirkpatrick, Luna Gargani, Vicki Noble, Gino Soldati, Roberto Copetti, Belaid Bouhemad, Angelika Reissig.




- Lung ultrasound is a clinically useful tool to rule in pneumonia; however, lung ultrasound does not rule out consolidations that do not reach the pleura.

B-D4-S8 (strong: level C)

- Lower-frequency ultrasound scanning may allow for better evaluation of the extent of a consolidation.

Evaluation of lung ultrasound for the diagnosis of pneumonia in the ED



Stefano Parlamento MD^{a,*}, Roberto Copetti MD^a, Stefano Di Bartolomeo MD^b

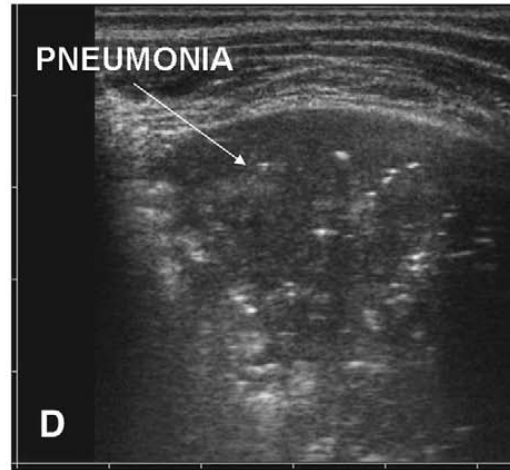
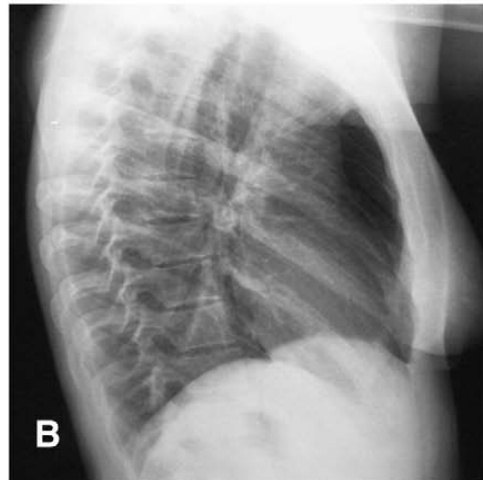
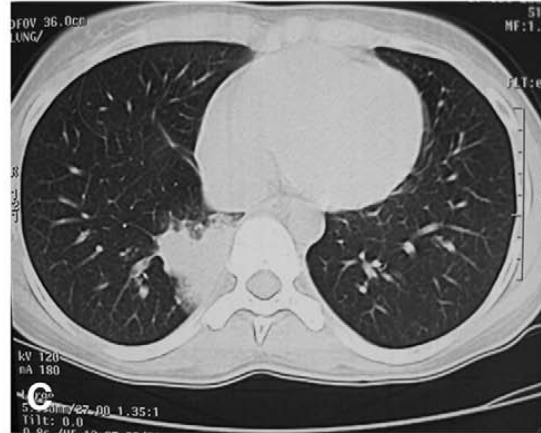
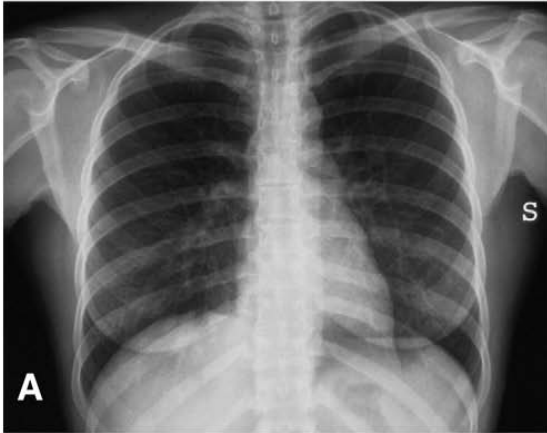

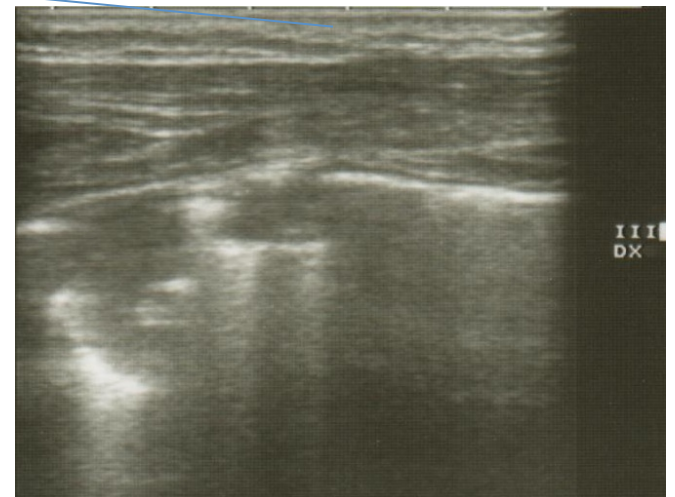
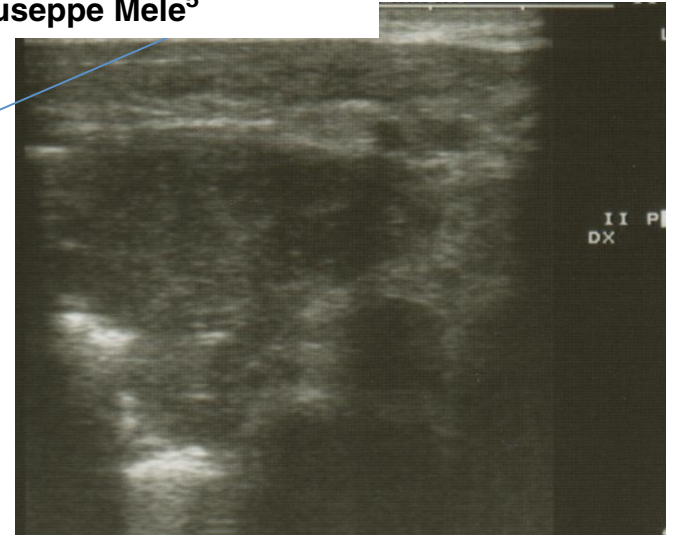
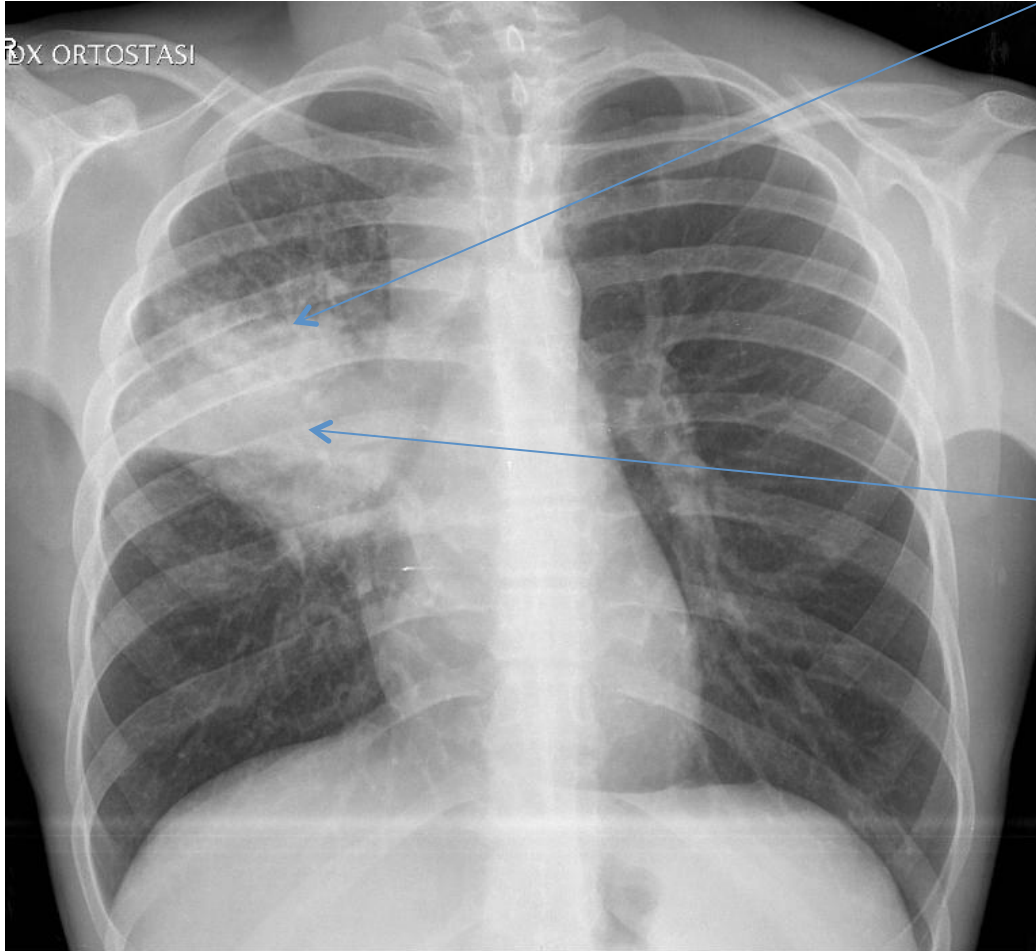
Table 1 Results of the instrumental examinations

	RX+	RX-	Total	US+, CXR-
ECO+	23	8	31	CT+ 8
ECO-	1	17	18	CT- 0
Total	24	25	49	Total 8

CT, computed tomography; CXR, chest x-ray; US, lung ultrasound. Findings in the group examined with CT are listed in right side of the table.

Lung Ultrasound Characteristics of Community-Acquired Pneumonia in Hospitalized Children

Vito Antonio Caiulo,^{1*} Luna Gargani,² Silvana Caiulo,³ Andrea Fisicaro,³
Fulvio Moramarco,¹ Giuseppe Latini,⁴ Eugenio Picano,² and Giuseppe Mele⁵



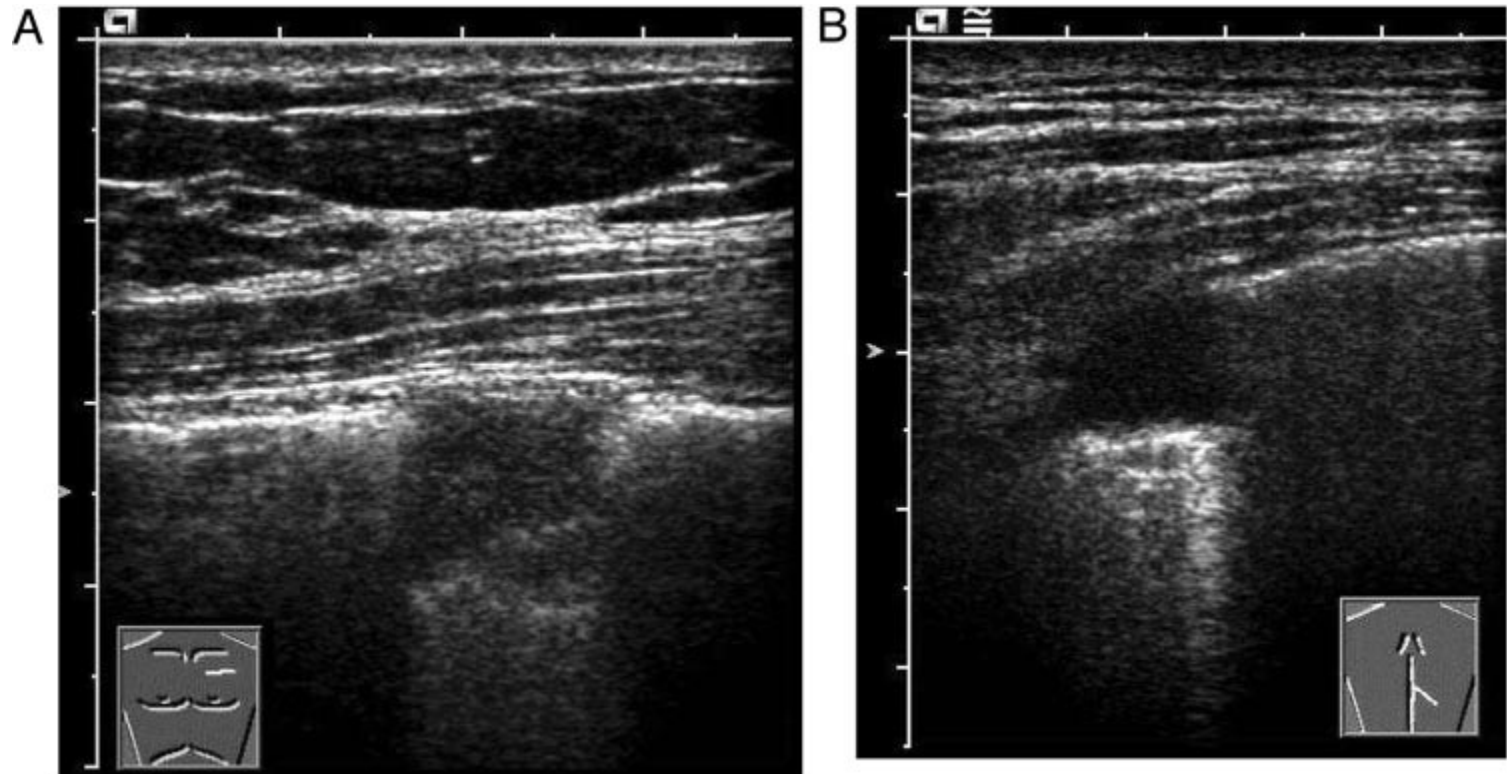
Pulmonary embolism

Thoracic Ultrasound for Diagnosing Pulmonary Embolism*

A Prospective Multicenter Study of 352 Patients

Gebhard Mathis, MD; Wolfgang Blank, MD; Angelika Reißig, MD; Peter Lechleitner, MD; Joachim Reuß, MD; Andreas Schuler, MD; and Sonja Beckh, MD

specificity 95%





Accuracy of Point-of-Care Multiorgan Ultrasonography for the Diagnosis of Pulmonary Embolism

Peiman Nazerian, MD; Simone Vanni, MD, PhD; Giovanni Volpicelli, MD, FCCP; Chiara Gigli, MD; Maurizio Zanobetti, MD; Maurizio Bartolucci, MD; Antonio Ciavattone, MD; Alessandro Lamorte, MD; Andrea Veltri, MD; Andrea Fabbri, MD; Stefano Grifoni, MD

357 pts with suspected PE, final diagnosis in 30.8%

	Sensitivity (%)	Specificity (%)
Echocardiography	32.7	90.9
Lung ultrasound	60.9	95.9
Vein ultrasound	52.7	92.6
Multi-organ ultrasound	90	86.2

Clinical applications

1. Heart Failure

- Diagnosis
- Follow-up
- Prognosis

2. ARDS

3. Pneumonia (consolidations)

4. Dialysis

5. Pulmonary fibrosis

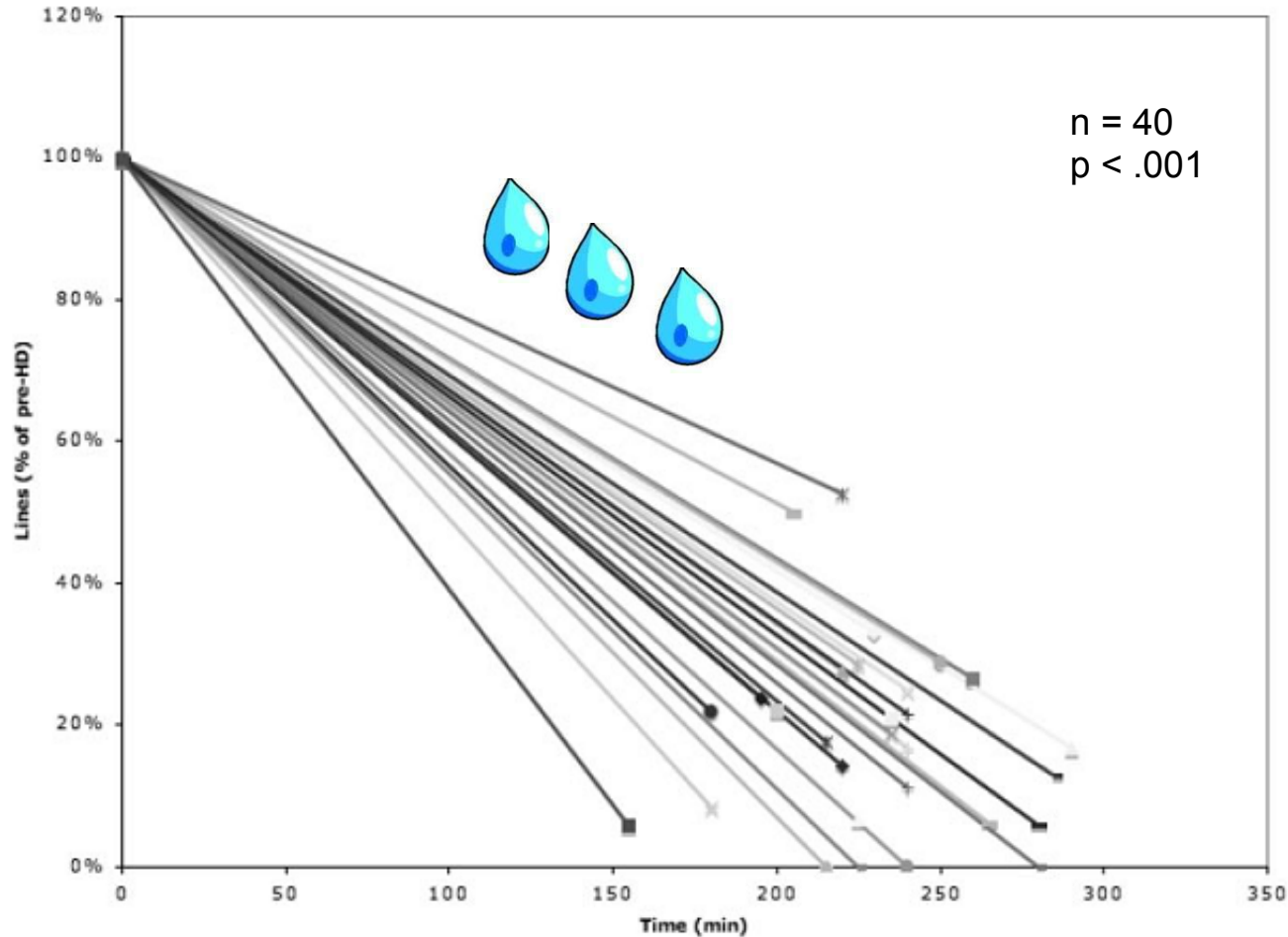
Ultrasound Assessment for Extravascular Lung Water in Patients Undergoing Hemodialysis*

Time Course for Resolution

microconvex probe



feasibility = 100%
10-15 mins

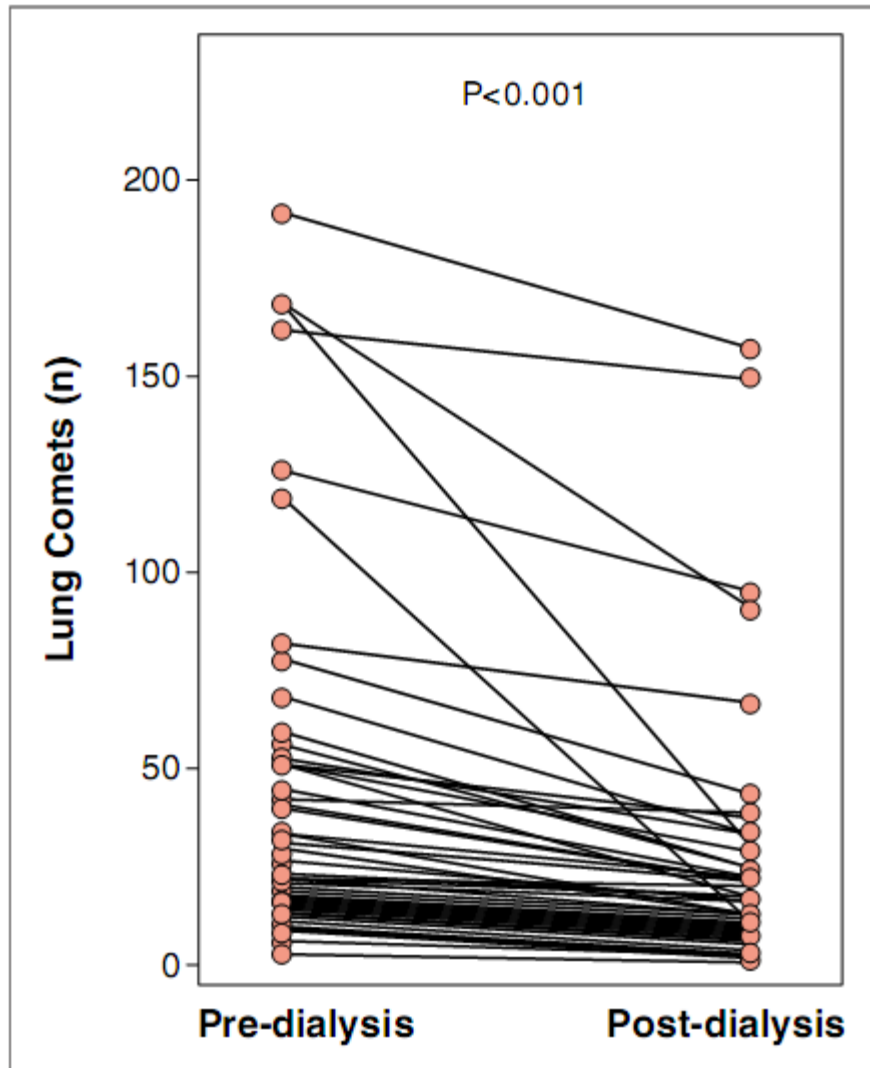


Detection of Pulmonary Congestion by Chest Ultrasound in Dialysis Patients



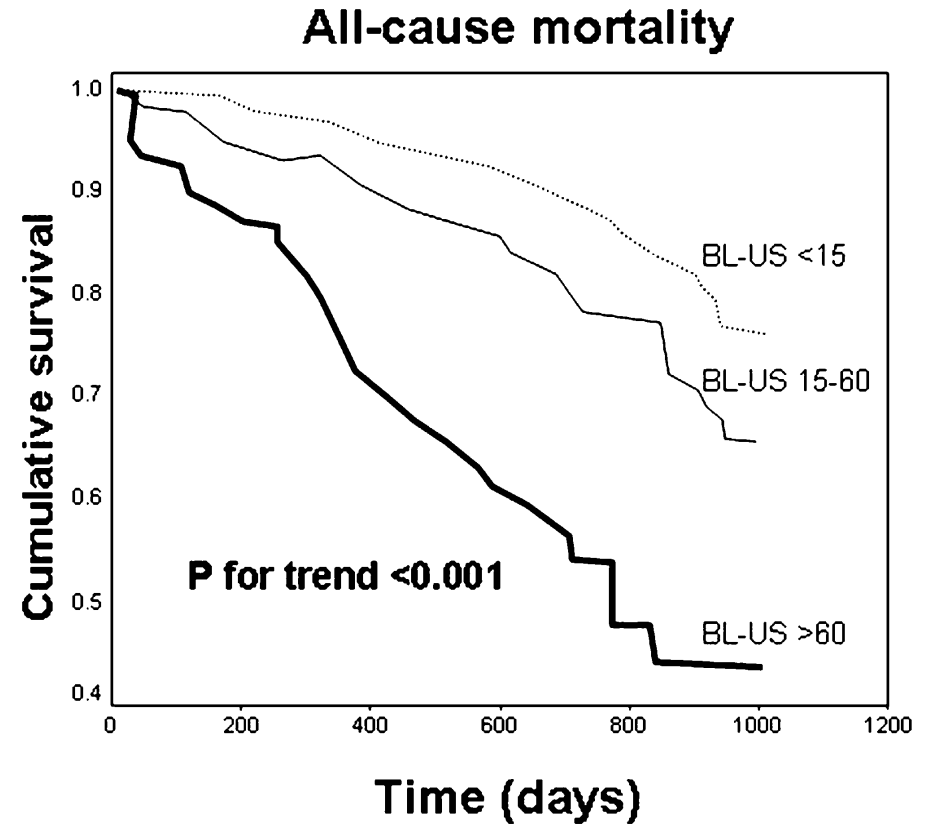
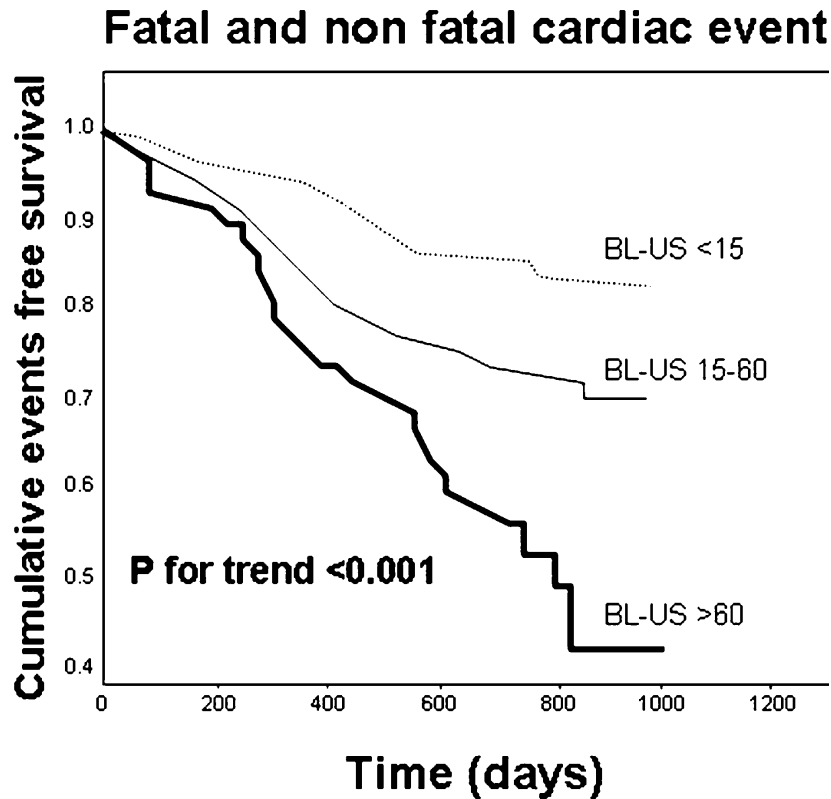
cardiac probe

Francesca Mallamaci, MD,*† Francesco A. Benedetto, MD,‡ Rocco Tripepi,†
Stefania Rastelli, MD,§ Pietro Castellino, MD PROF.,§ Giovanni Tripepi, STAT. DR.,†
Eugenio Picano, MD PROF.,|| Carmine Zoccali, MD PROF.*†



- $n = 75$
- feasibility = 100%
- mean time needed = 4 mins (range 3-6)

Prognosis in dialysis



Future directions



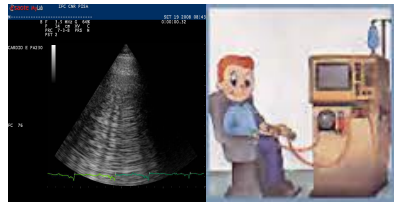
EUropean REnal and CARdiovascular Medicine
Working Group

**Lung water by Ultra-Sound-guided Treatment
to prevent death and cardiovascular complications
in high risk end-stage renal disease patients
with cardiomyopathy**



LUST

LUST



500 patients
with MI or HF

250 patients

US guided UF regimen
& drug treatment

250 patients

Control Group, standard
care

>15 lung comets

<15 lung comets

UF intensification
(longer and/or additional
dialyses)

Monitoring
Lung US at least 1/w until
the goal is achieved

Then, lung US 1/month

No UF intensification.
No change in drug
treatment.

Monitoring (monthly Lung US)

>15 lung comets

<15 lung comets

(continue monthly
lung US monitoring)

If after 3 – 4 months the treatment goal
is not achieved or the patient does not
tolerate UF, drug treatment
intensification or introduction will be
applied (see APPENDIX).

Clinical applications

1. Heart Failure

- Diagnosis
- Follow-up
- Prognosis

2. ARDS

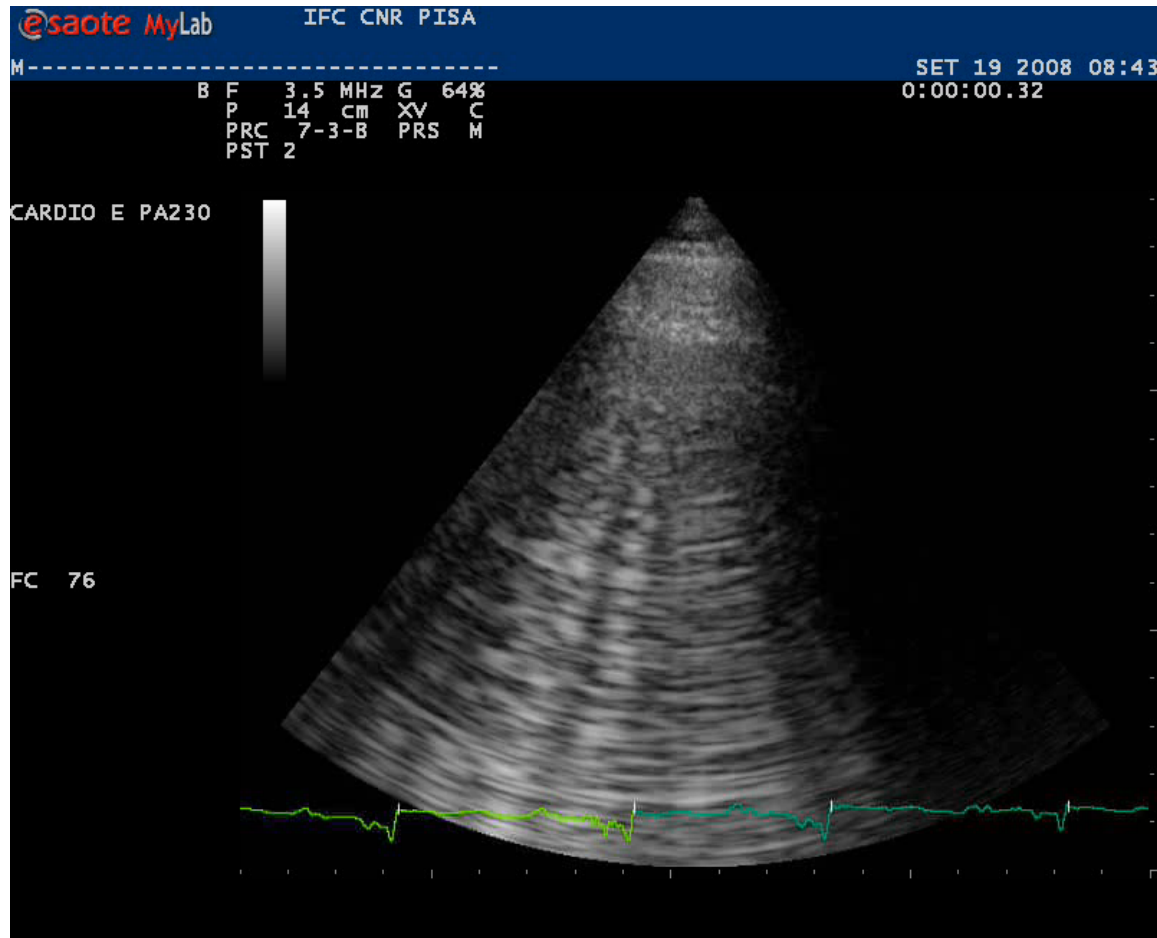
3. Pneumonia (consolidations)

4. Dialysis

5. Pulmonary fibrosis

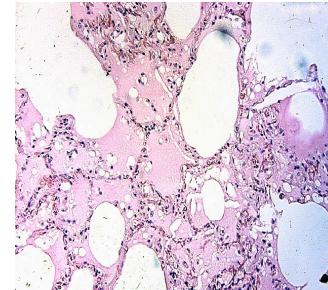
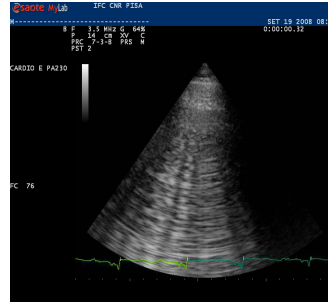
B-lines: definition

B-lines are the sonographic sign of the interstitial syndrome



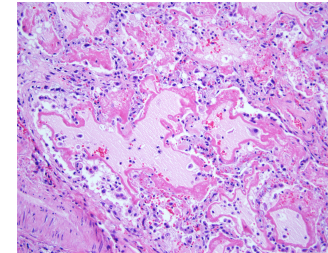
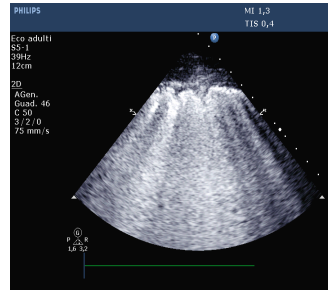
B-lines: a non-specific sign of interstitial syndrome

Cardiogenic pulmonary oedema



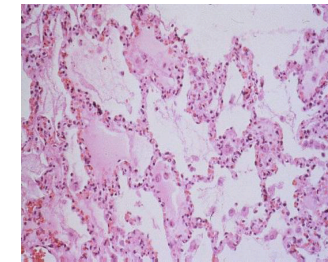
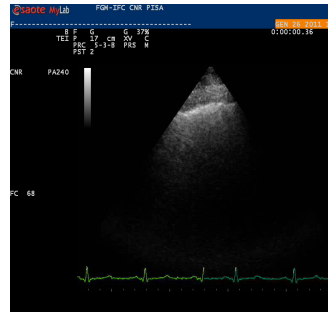
Transudate

Non-cardiogenic pulmonary oedema



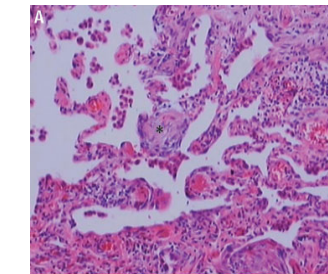
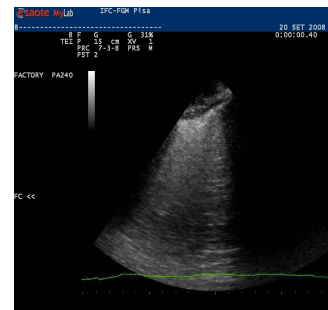
Essudate

Interstitial pneumonia



Essudate

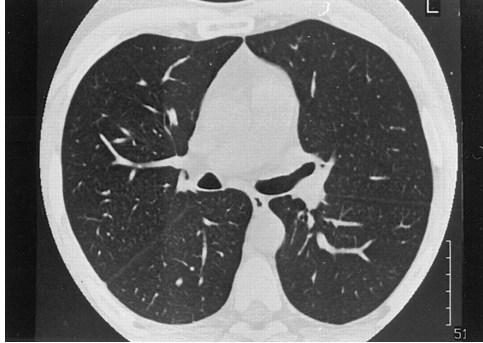
Pulmonary fibrosis



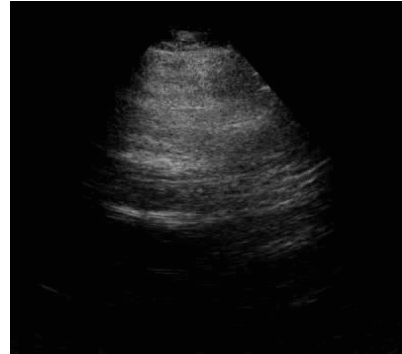
Collagen

Interstitial lung disease

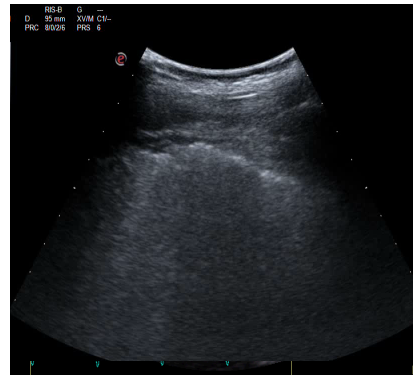
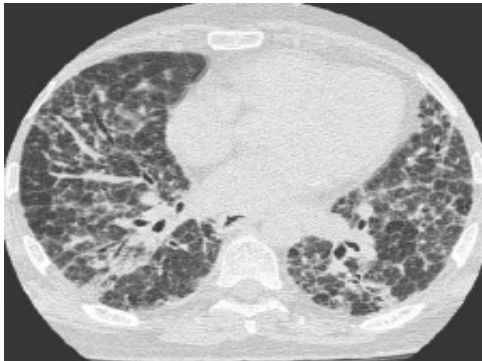HRCT



Lung
ultrasound



Normal
lung




Pulmonary
fibrosis

Lichtenstein D et al. *Am J Respir Crit Care Med.* 1997;156:1640

Volpicelli G. *Am J Emerg Med.* 2006;24:689-696



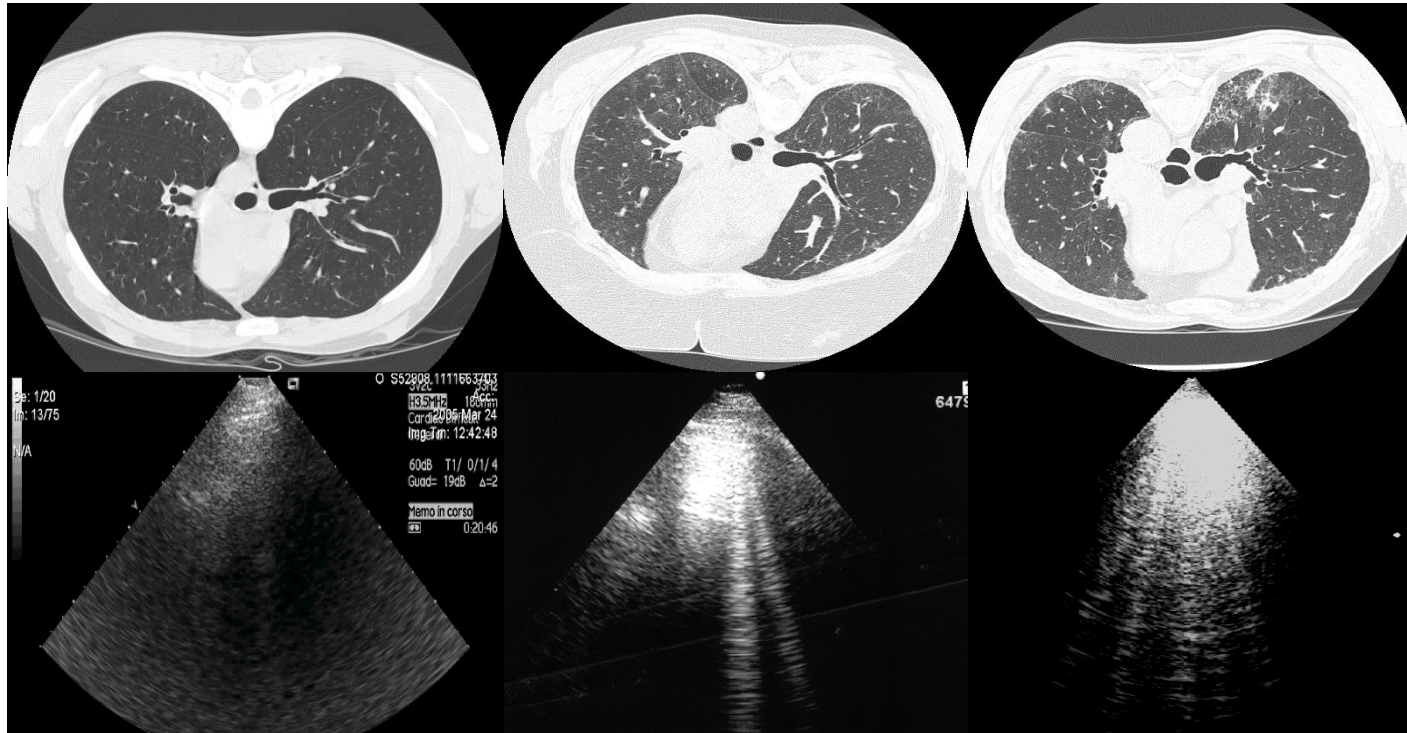
Correlation with chest CT



**No fibrosis:
Warrick = 0**

**Mild fibrosis:
Warrick = 8**

**Moderate/severe fibrosis:
Warrick = 14**



No B-lines

Mild B-lines

Moderate/severe B-lines

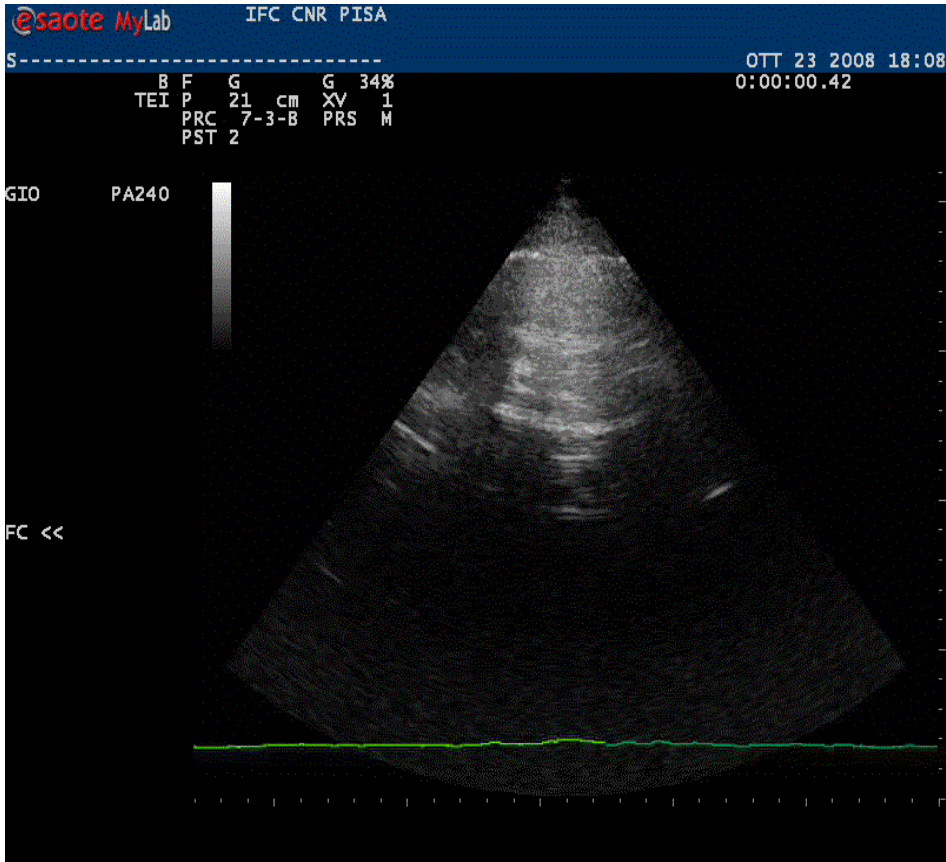
LUS in systemic sclerosis

58 SSc patients

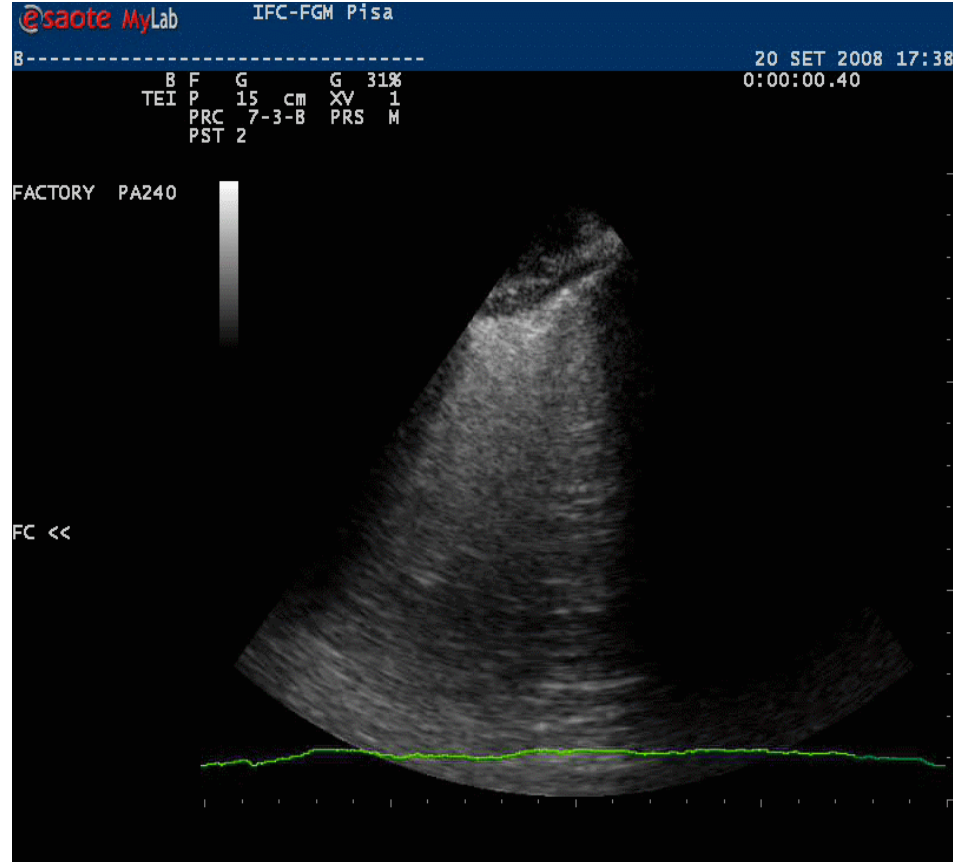
		HRCT	
		Positive	Negative
LUS	Positive	36	10
	Negative	0	12

sensitivity 100%

Which probe?

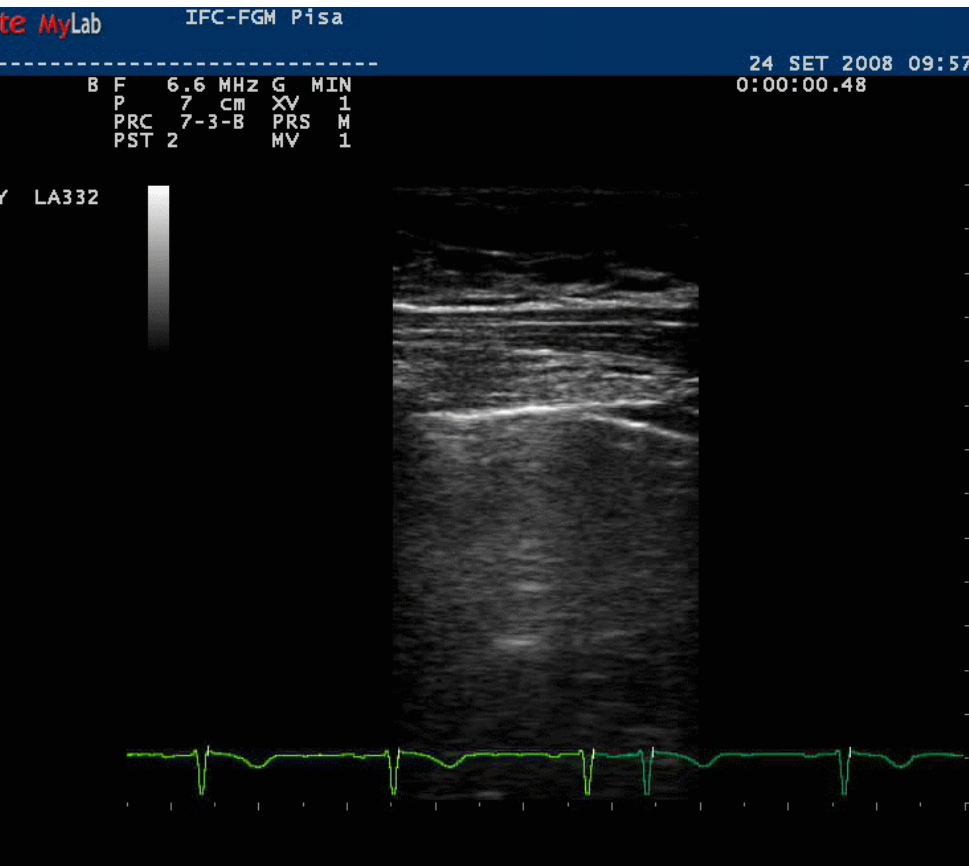


Normal lung

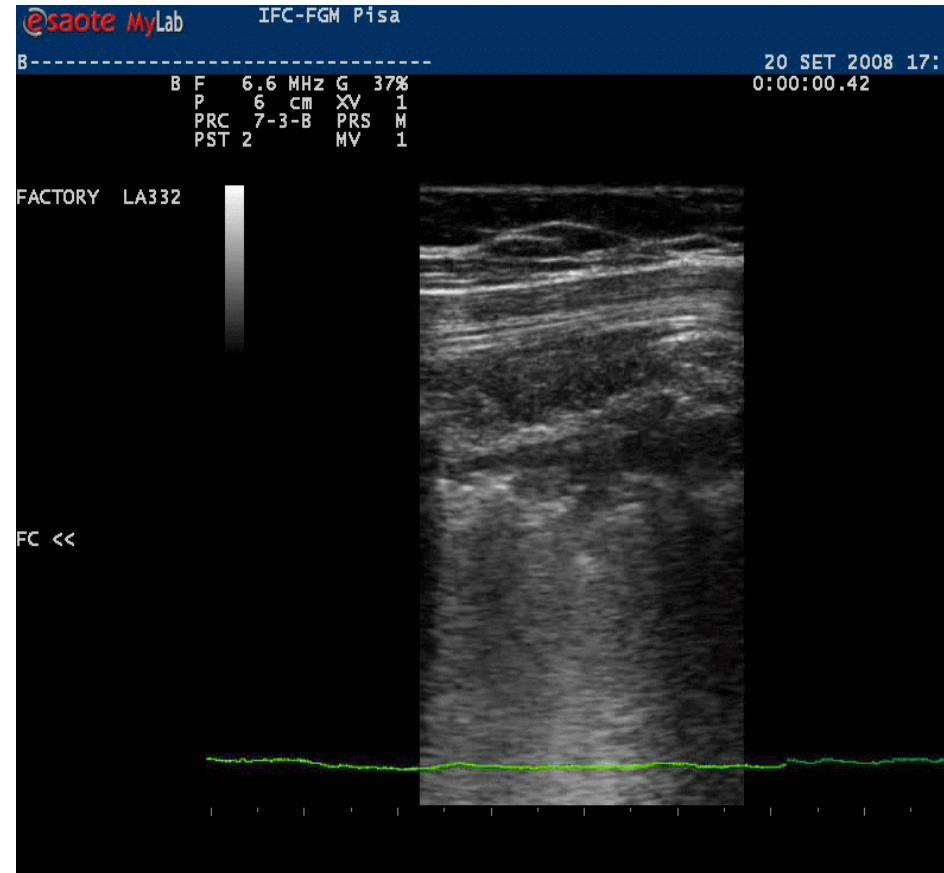


BL, 61 year-old, SSc diffuse form

Which probe?



AR, 54 year-old, normal lung



BL, 61 year-old, SSc diffuse form

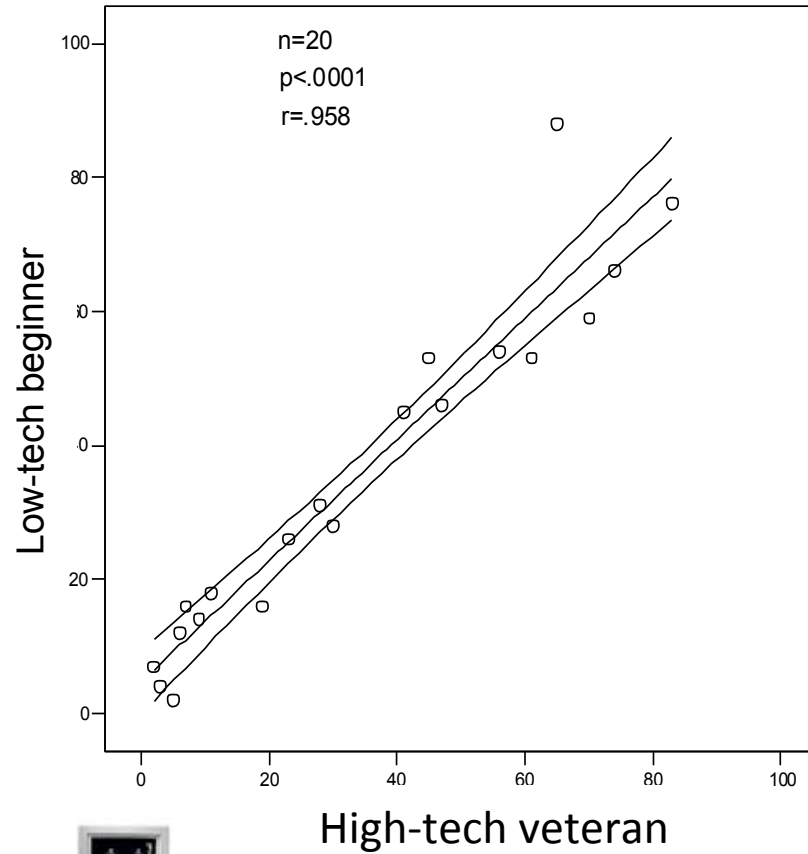
Limitations

- **Operator-dependance**

Inter-observer variability



(<1 hour experience)



(>2 years experience)

Limitations

- **Operator-dependance**
- **Position**

Position

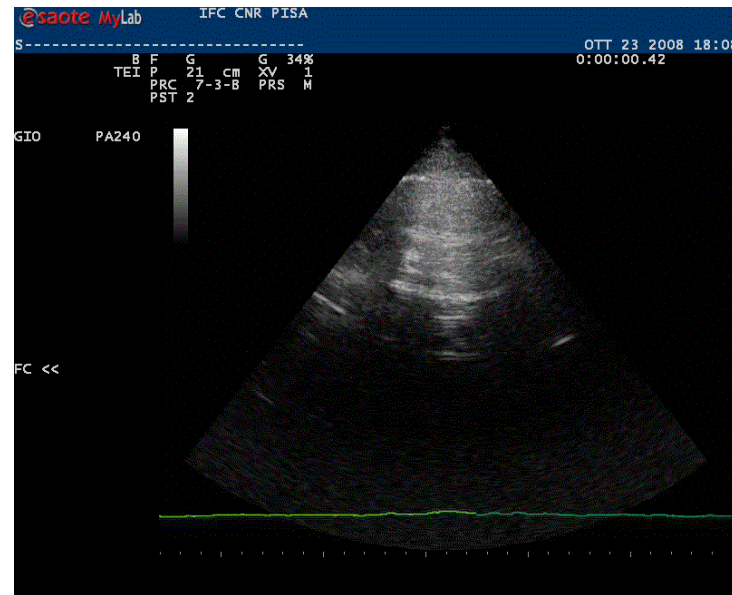
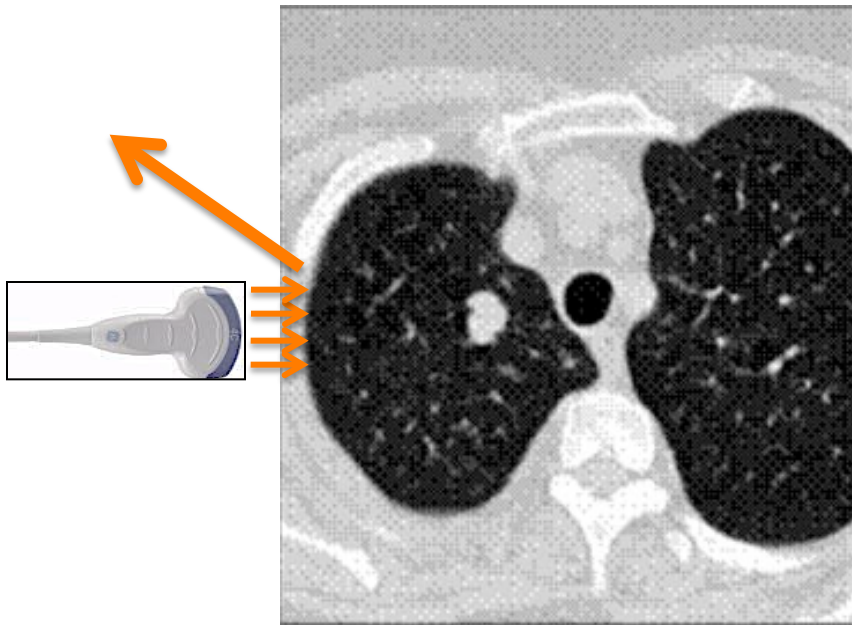
International Evidenced-based Recommendations for Point-of-Care Lung Ultrasound

Writing Committee:

Giovanni Volpicelli (Chairperson)*, Daniel Lichtenstein, Gebhard Mathis, Andrew Kirkpatrick, Luna Gargani, Vicki Noble, Gino Soldati, Roberto Copetti, Belaid Bouhemad, Angelika Reissig.



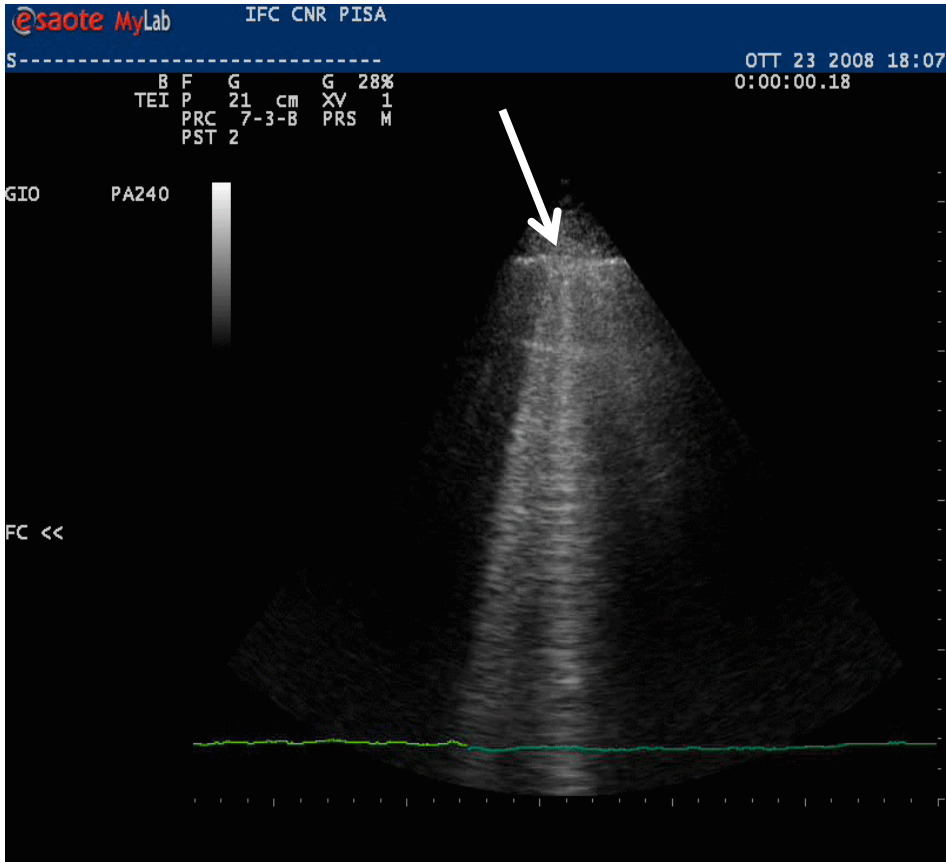
<Lung ultrasound does not rule out alterations that do not reach the pleura>



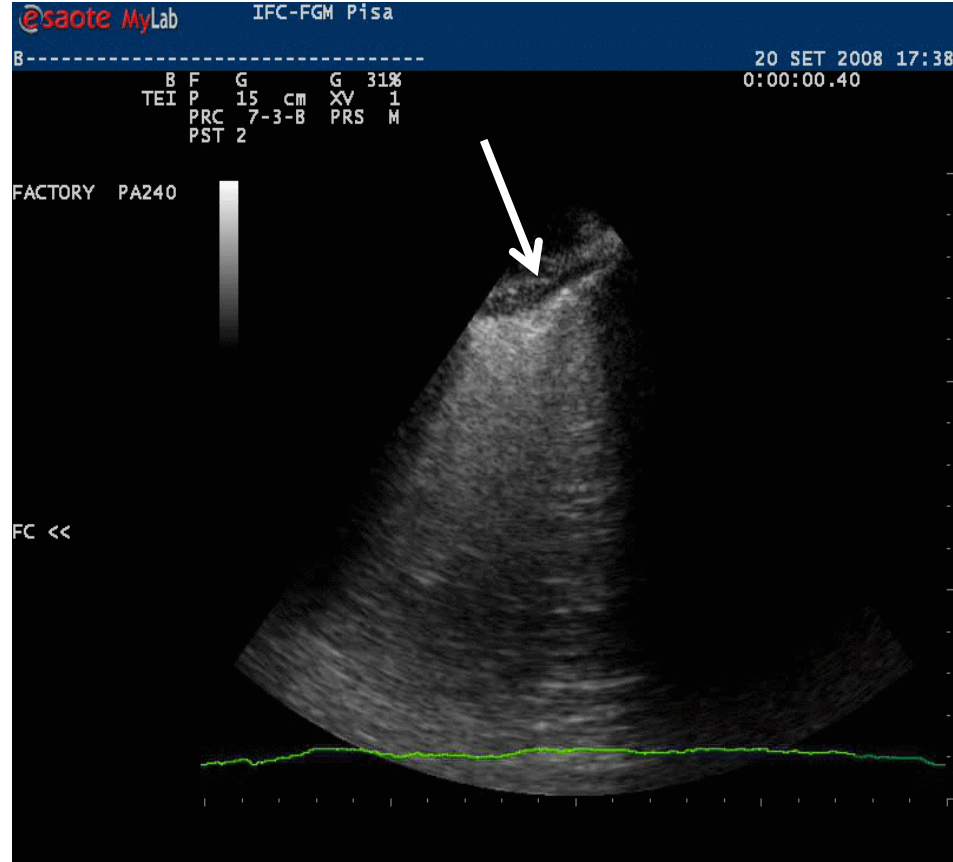
Limitations

- **Operator-dependance**
- **Position**
- **Specificity**

Watery or fibrotic B-lines?

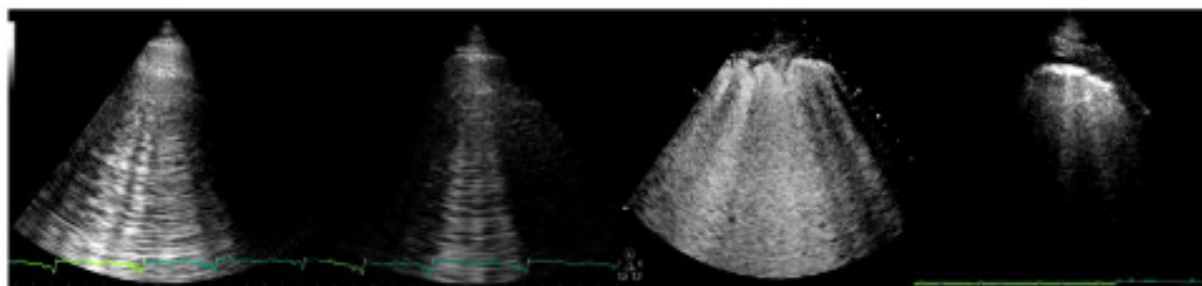


Decompensated heart failure



Pulmonary fibrosis

Lung ultrasound: a new tool for the cardiologist



	Acute cardiogenic pulmonary edema	Chronic heart failure	ALI/ARDS	Pulmonary fibrosis
Clinical setting	acute	chronic	acute	chronic
B-lines number	++++	+ / ++ / +++	++++	+ / ++ / +++
B-lines distribution	multiple, diffuse, bilateral (white lung)	multiple, diffuse, bilateral, following decubitant regions (black and white lung)	non-homogeneous distribution, presence of spared areas	more frequently posterior at lung basis
Other LUS signs	pleural effusion	pleural effusion	pleural effusion, pleural alterations, parenchymal consolidations of various size	pleural thickening
Echocardiogram	abnormal	abnormal	likely normal	likely normal

ALI = acute lung injury; ARDS = acute respiratory distress syndrome; LUS = lung ultrasound.

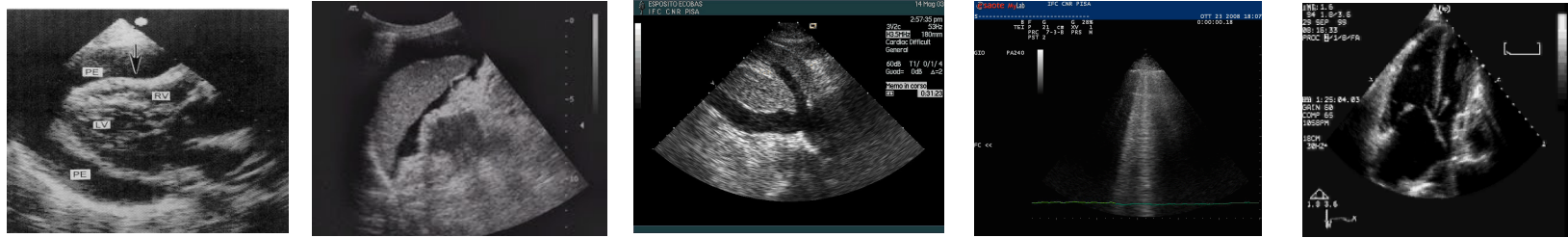


Table 2 The list of nine possible ultrasound patterns diagnosed in patients admitted for undifferentiated hypotension and the corresponding combination of findings detected at multiorgan point-of-care ultrasonographic evaluation

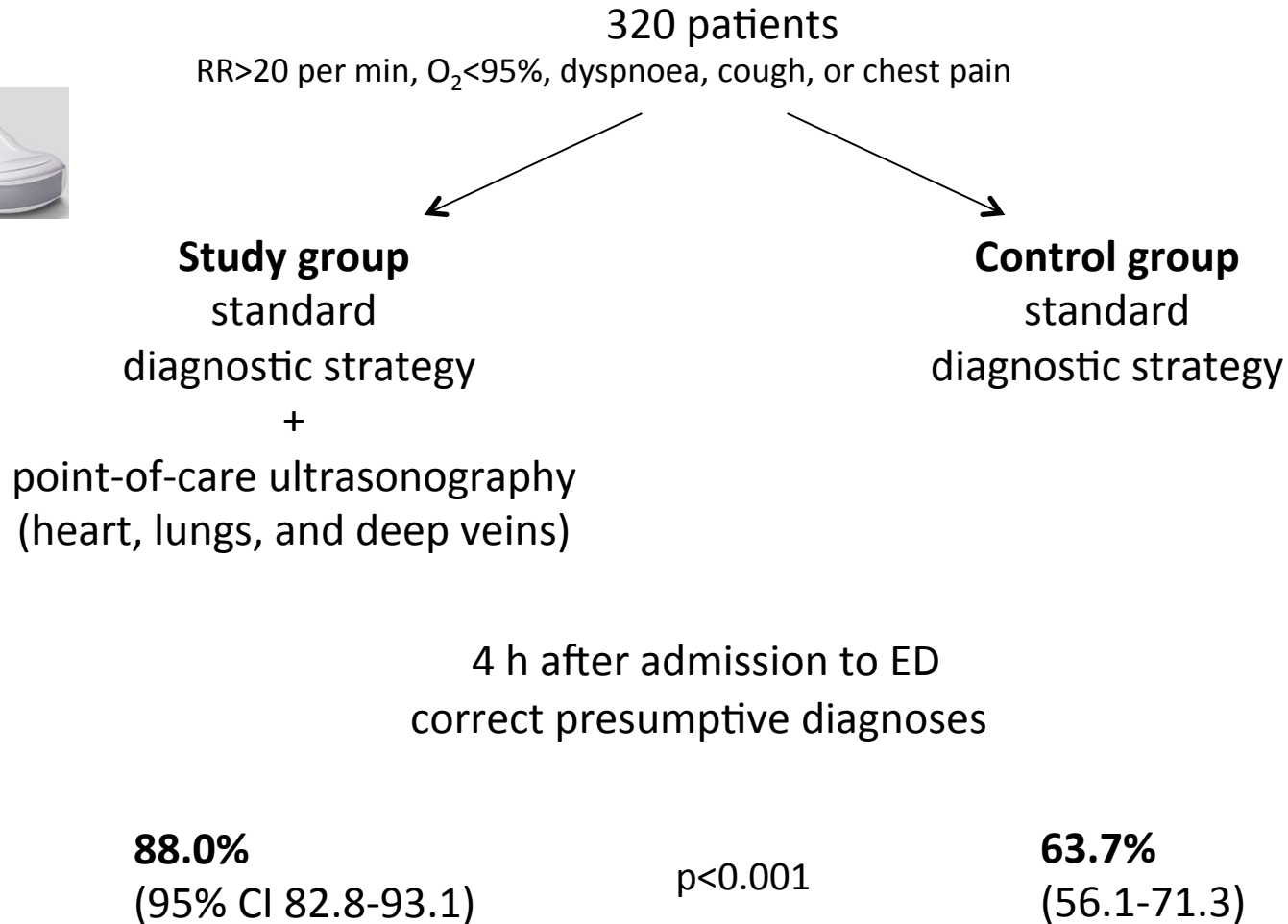
Ultrasound pattern	Organ evaluation	Corresponding signs
Hypovolemic	Heart Inferior vena cava Lungs Abdomen	Hyperkinetic LV ^a Diam. <2 cm + Resp. collapse >50 % ^a A pattern ^a Free fluids/Aortic aneurysm ^a
Distributive	Heart Inferior vena cava Lungs	Hyperkinetic LV Diam. <2 cm + Resp. collapse >50 % B pattern with consolidation or consolidation with air bronchograms ^b
Hypovolemic/distributive	Heart Inferior vena cava Lungs Abdomen	Hyperkinetic LV ^a Diam. <2 cm + Resp. collapse > 50 % ^a A/B pattern ^a Free fluids ^a
Obstructive cardiac tamponade	Heart	Pericard. effusion with tamponade
Obstructive pulmonary embolism	Heart Inferior vena cava Lungs Peripheral veins	Dilated/Hypokinetic RV ^a Sludge or no respiratory collapse and max. diam. >2 cm ^a A pattern ^a Deep vein thrombosis ^a
Obstructive tension pneumothorax	Heart Inferior vena cava Lungs	Dilated/Hypokinetic RV Sludge or no respiratory collapse and max. diam. >2 cm No sliding and pulse, no B-lines, no consolidation ^b
Cardiogenic	Heart Lungs	Hypokinetic left ventricle B pattern ^b
Mixed	Pattern where criteria for more than a single diagnosis are satisfied (other than hypovolemic/distributive)	
Indefinite	Pattern where criteria for a single diagnosis are not satisfied or uncertain	

LV left ventricle, RV right ventricle

^a At least two of these signs

^b Necessarily present

Point-of-care ultrasonography in patients admitted with respiratory symptoms: a single-blind, randomised controlled trial.



Toward an integrated ultrasound approach

Focused, point-of-care, whole-body ultrasound

