

# Handsonecho Courses

Partim

Gastrointestinal Ultrasound

23/09/2015

Prof. Dr. Harald Peeters

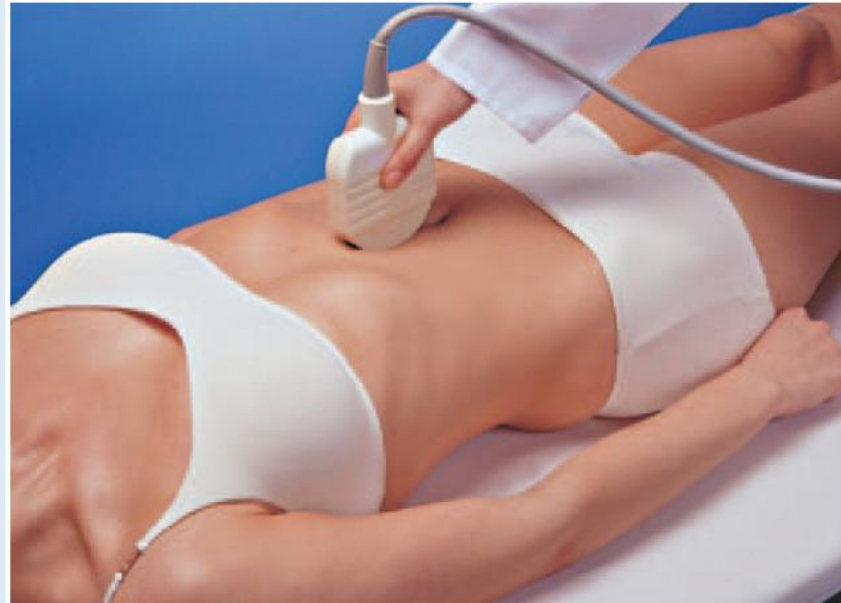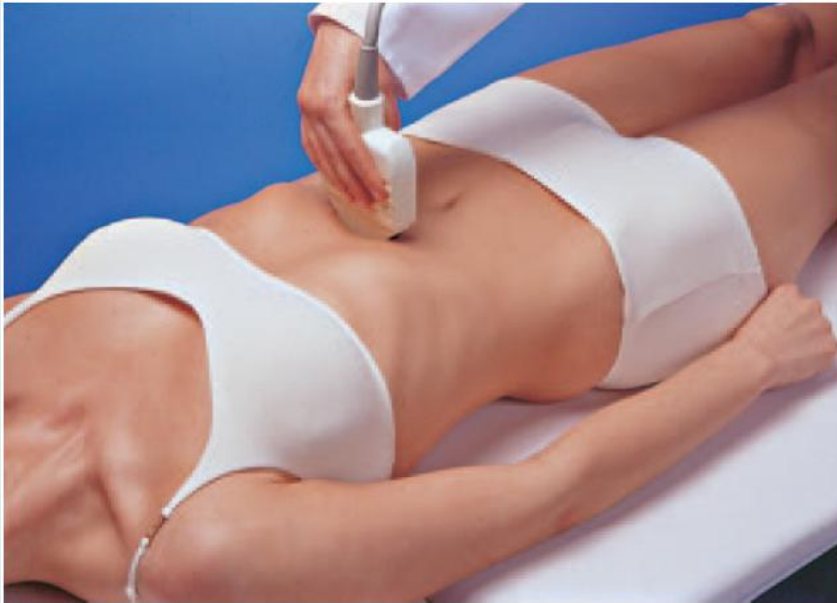Gastro-enterologie

AZ St-Lucas Gent

# Algemene beschouwingen

- **Positie:**

- Transversaal: links = rechterzijde patiënt, rechts = linkerzijde patiënt
- Sagittaal: links = craniaal, rechts = caudaal
- Echokop op 12.00u en 11.45u, soms ook op 11.40u of 11.50u



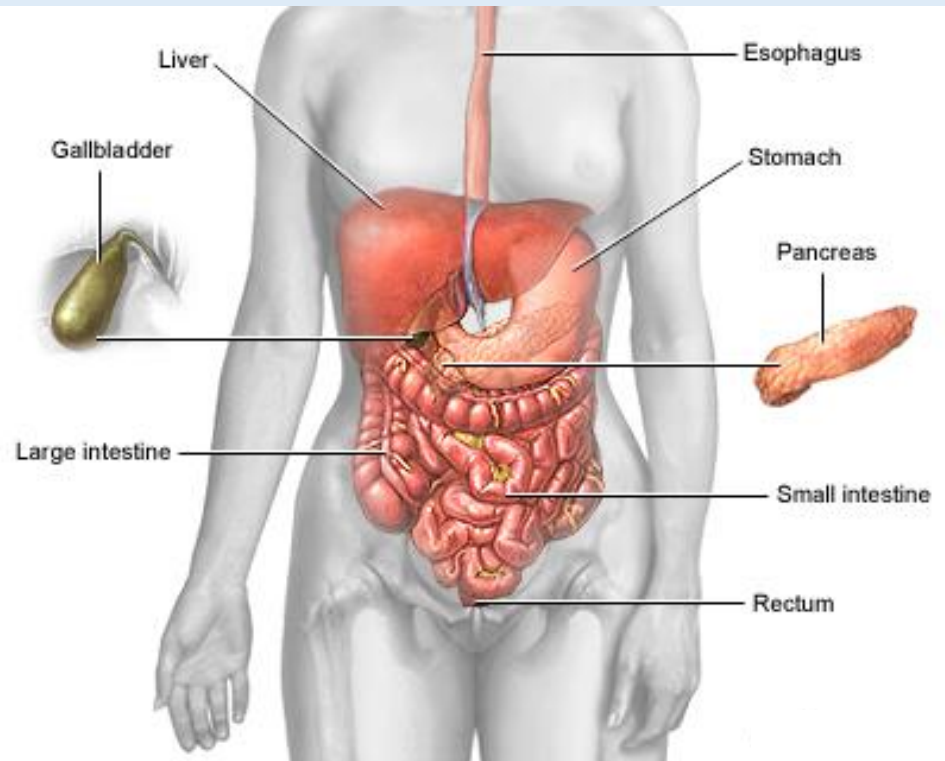
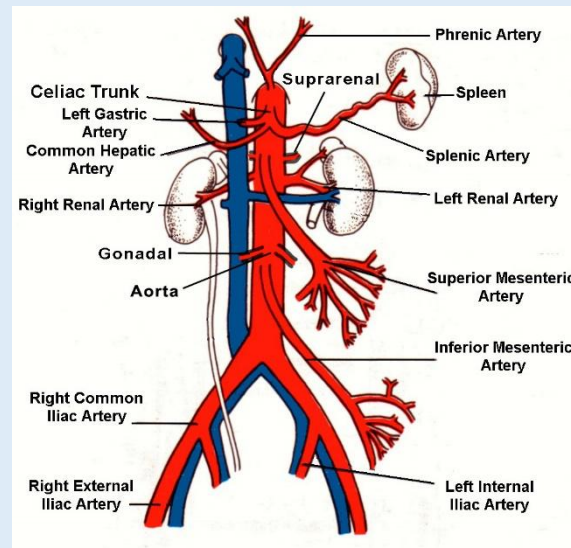
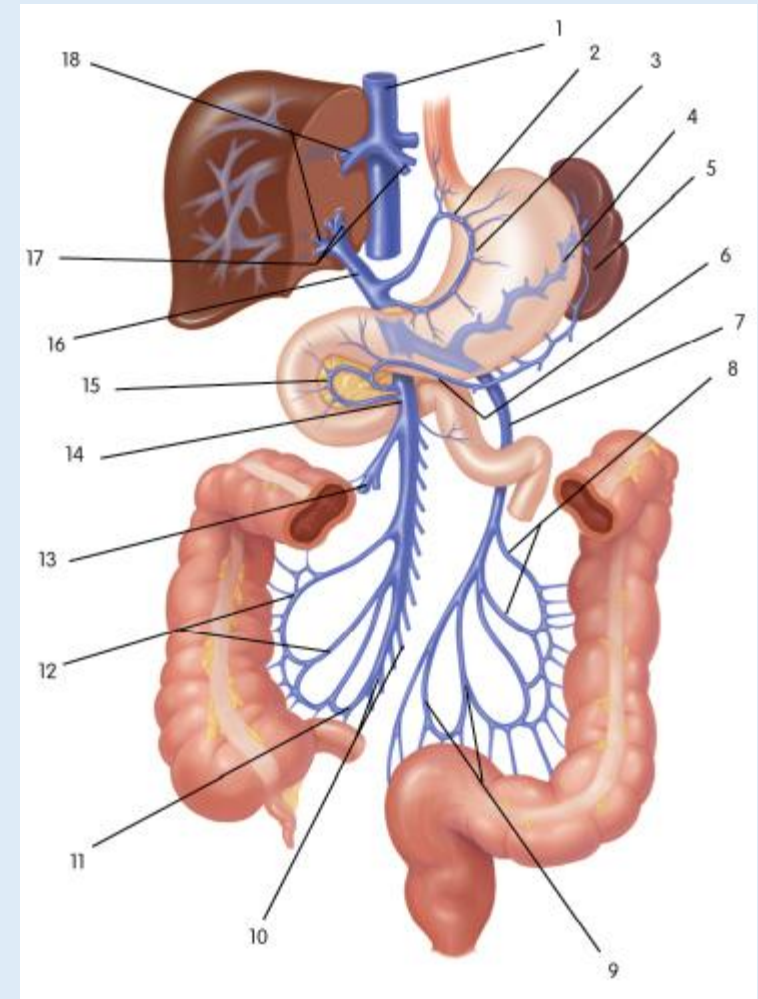
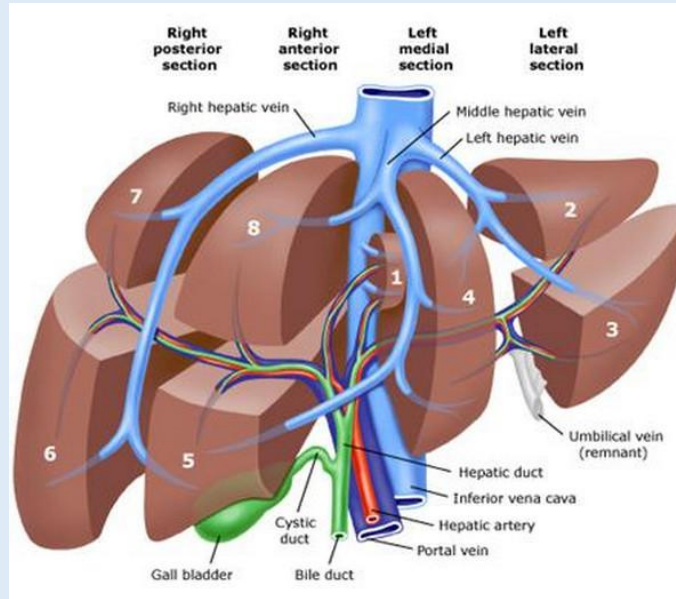
# Algemene beschouwingen

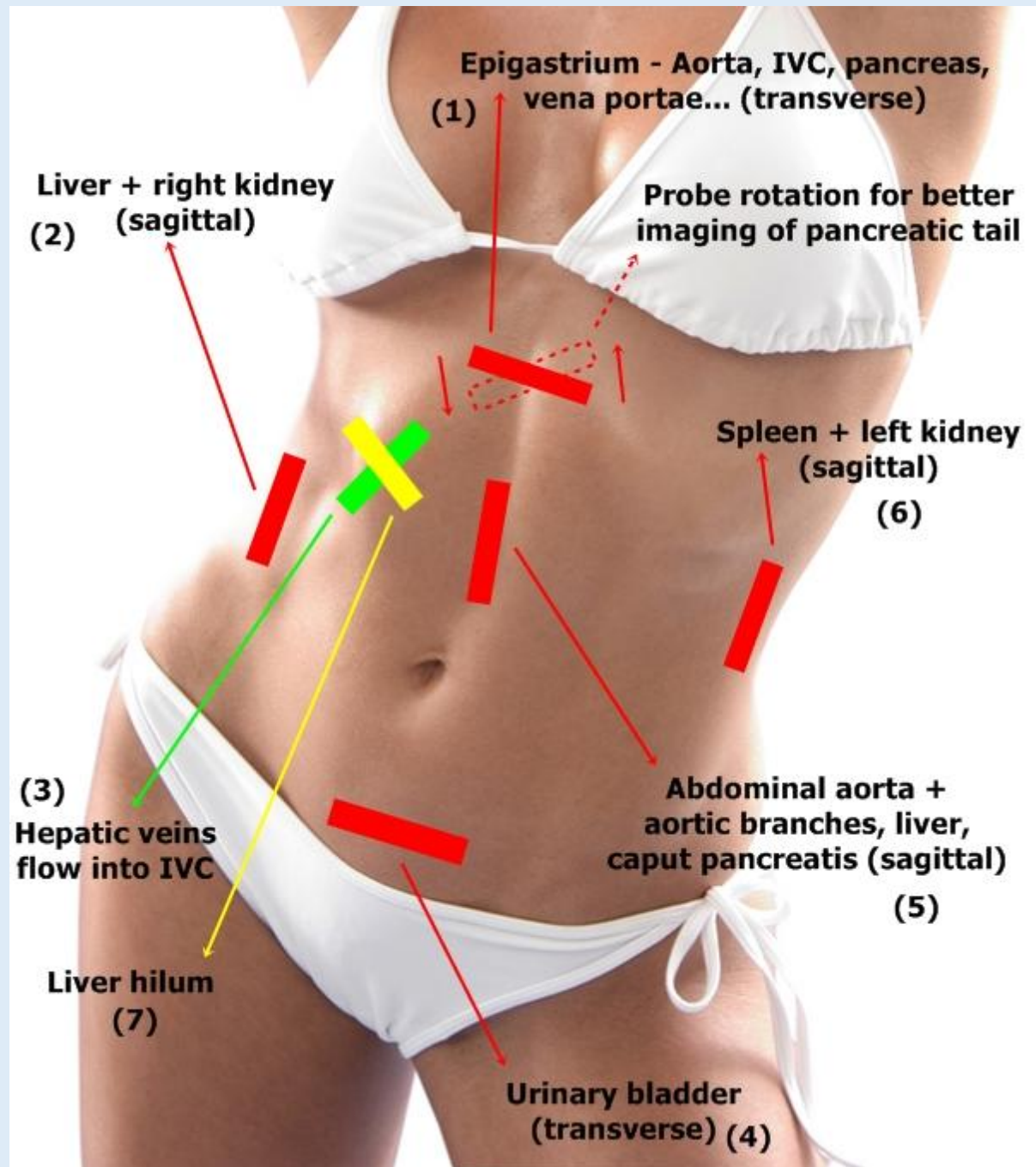
- **Systematiek:**

1. Aorta – Vena cava (sagittaal)
2. Lever: links -> hilus -> rechts
3. Galblaas en galwegen
4. Rechter nier
5. Linker nier
6. Milt – pancreasstaart
7. Pancreas
8. Aorta – Vena cava (transversaal) / iliacale vaten
9. Klein bekken (blaas/uterus/prostaat/adnexen)
10. Intestinale structuren


# Algemene beschouwingen


Kennis anatomie = essentieel!



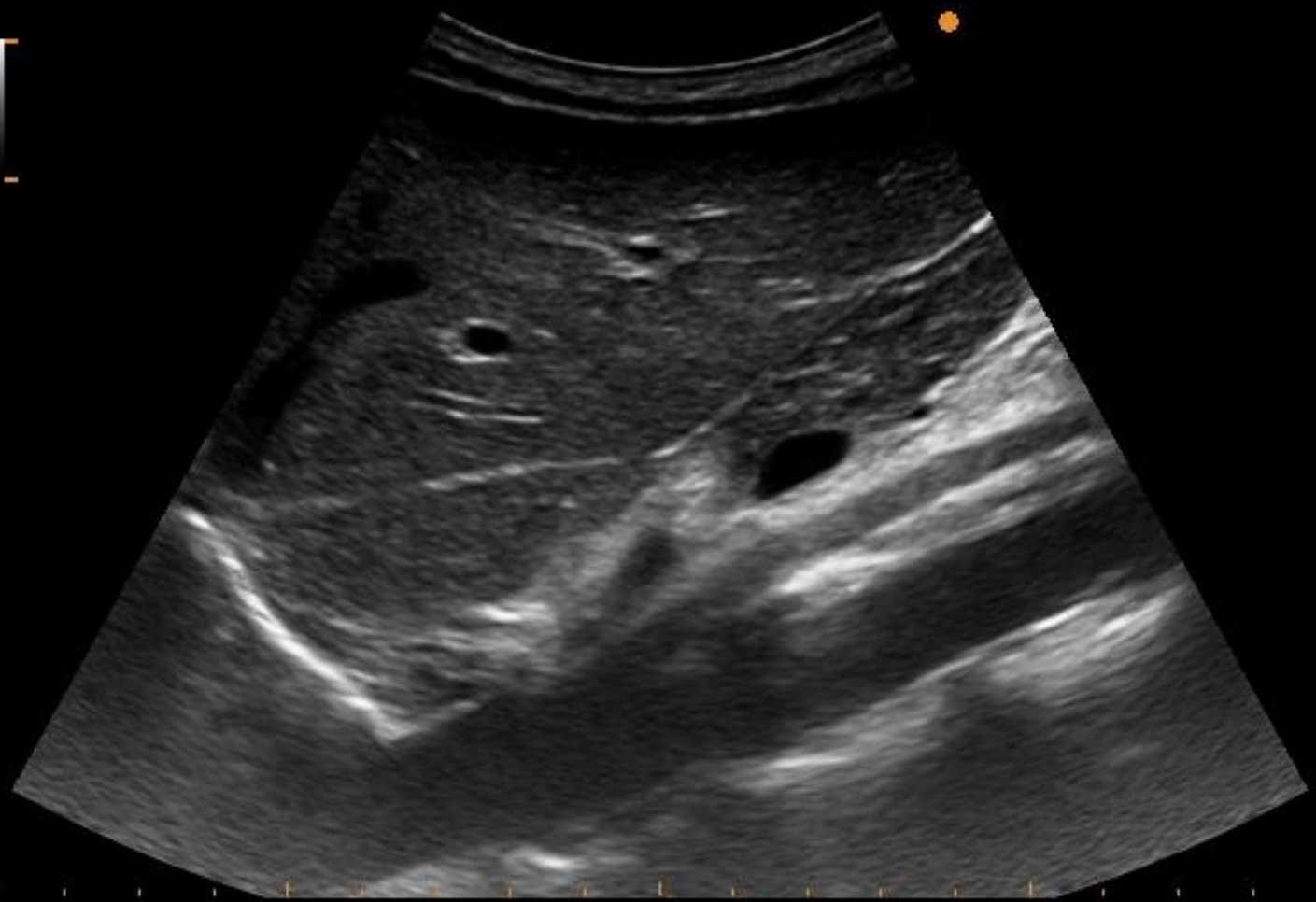


# Aorta (sagittaal)





70%



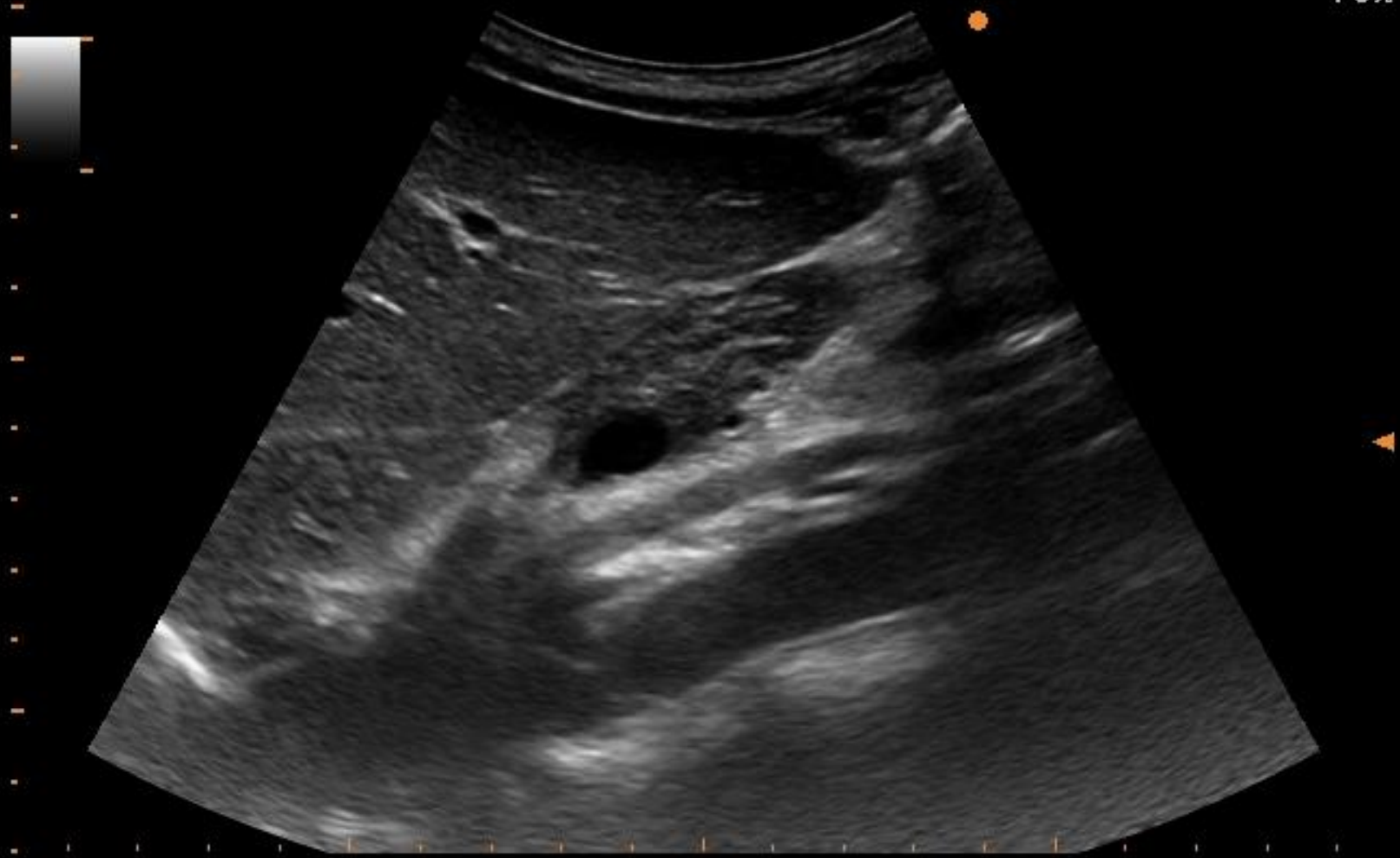
ALOKA A.Z. ST- LUCAS  
GENT

[Redacted]

Y

15/09/22  
09:51:53

70%





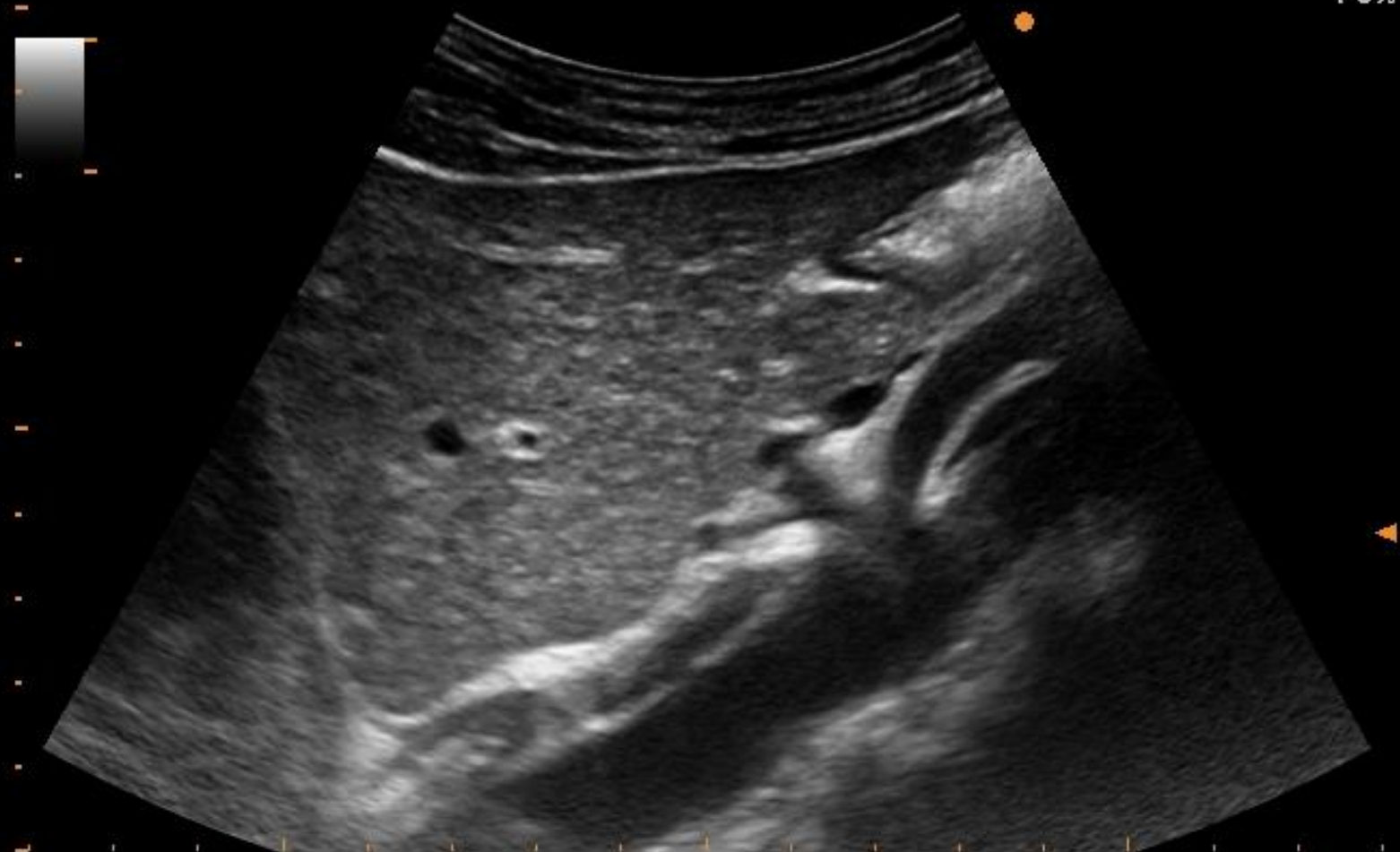ALOKA

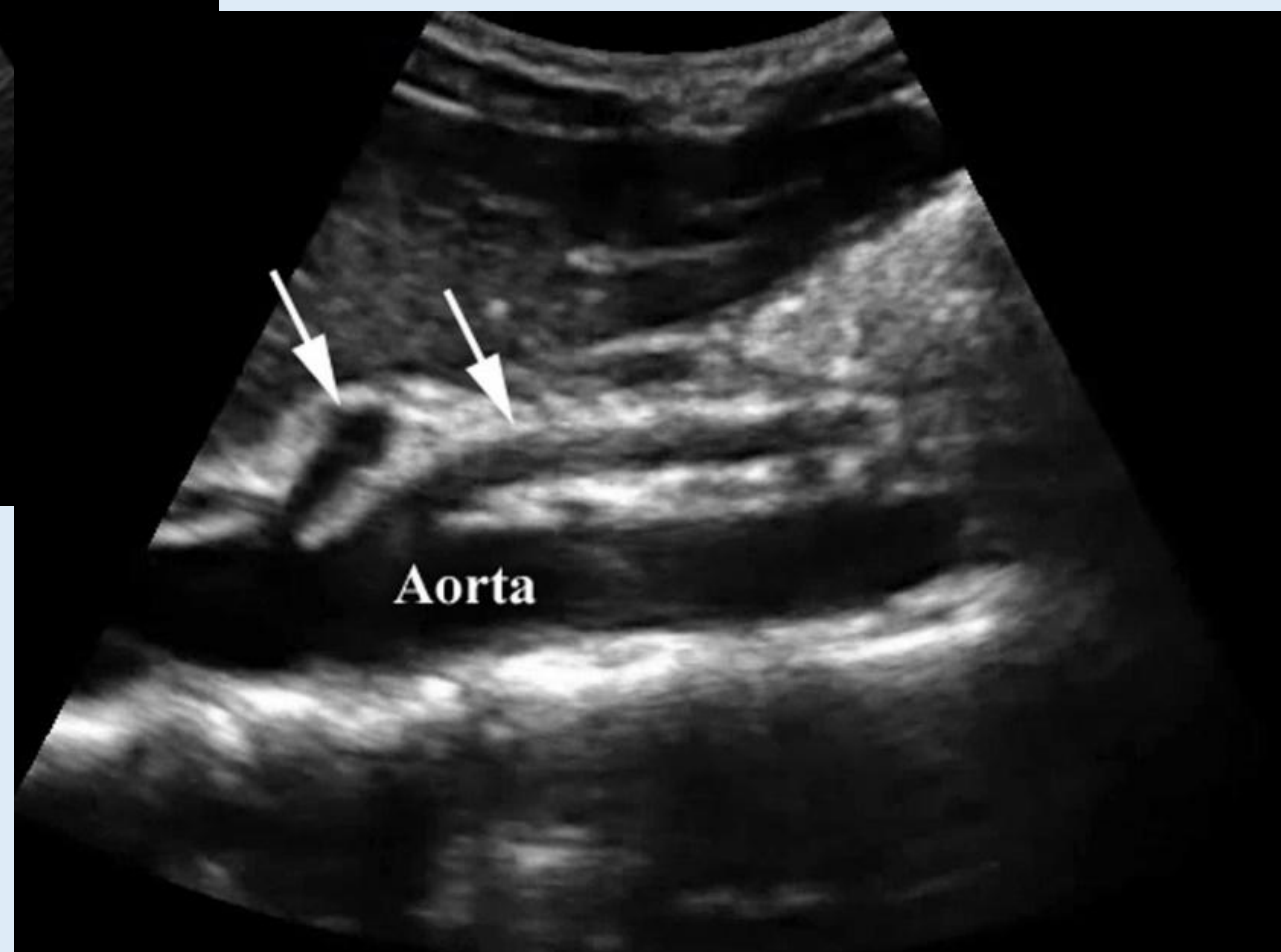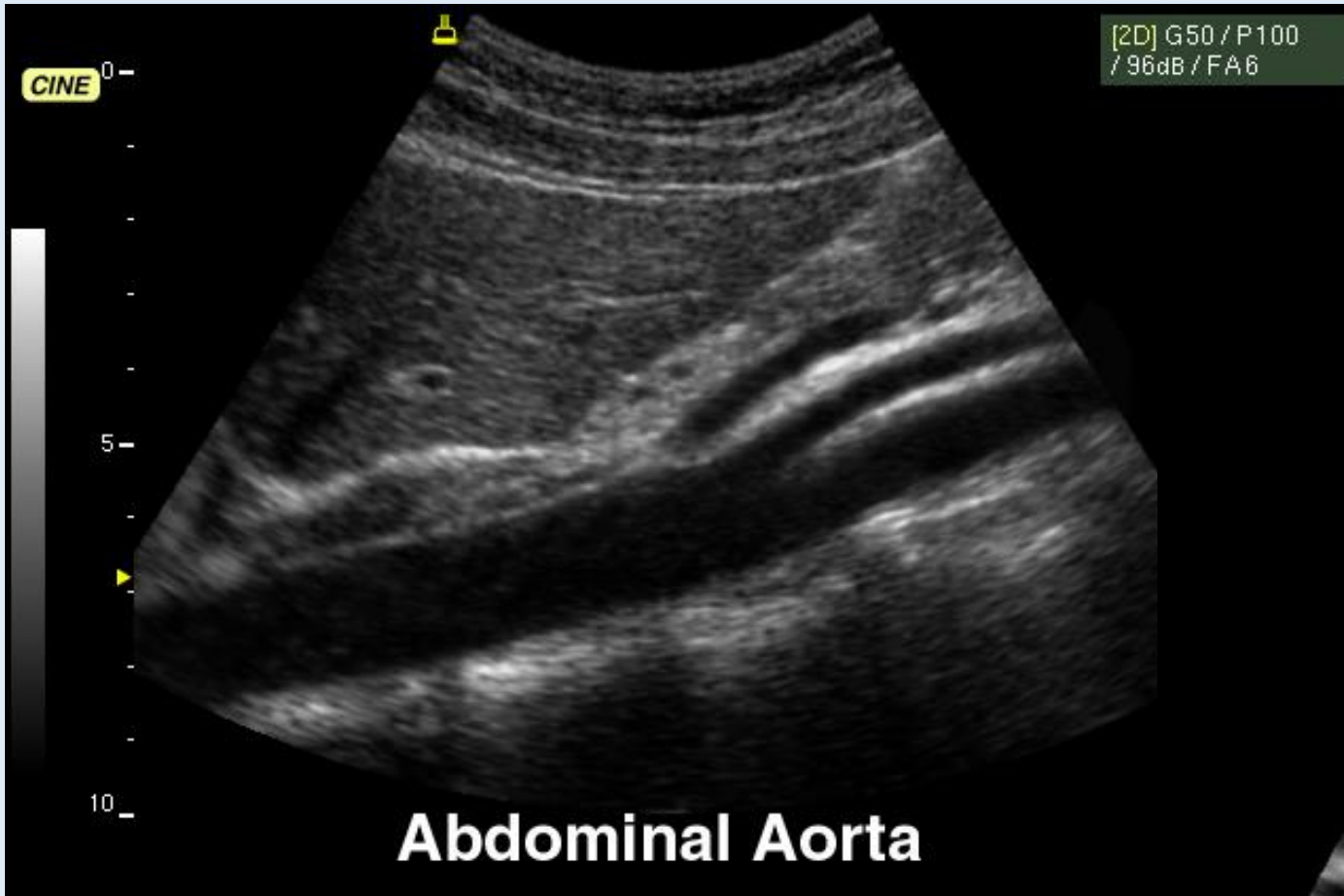
A.Z. ST- LUCAS  
GENT

: [ ] Y  
:

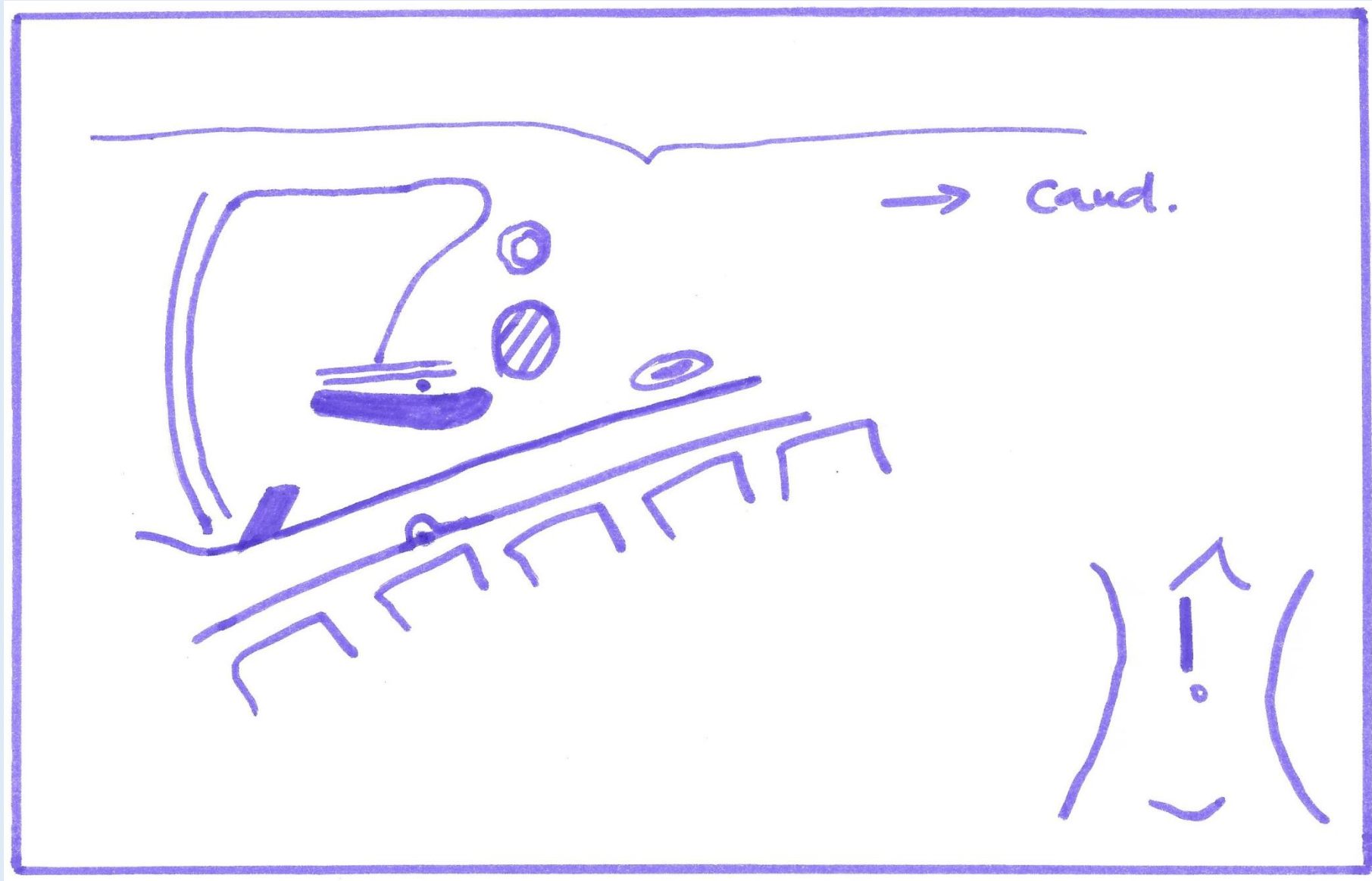
' 15/09/22  
10:49:13

70%





# Vena cava inferior (sagittaal)

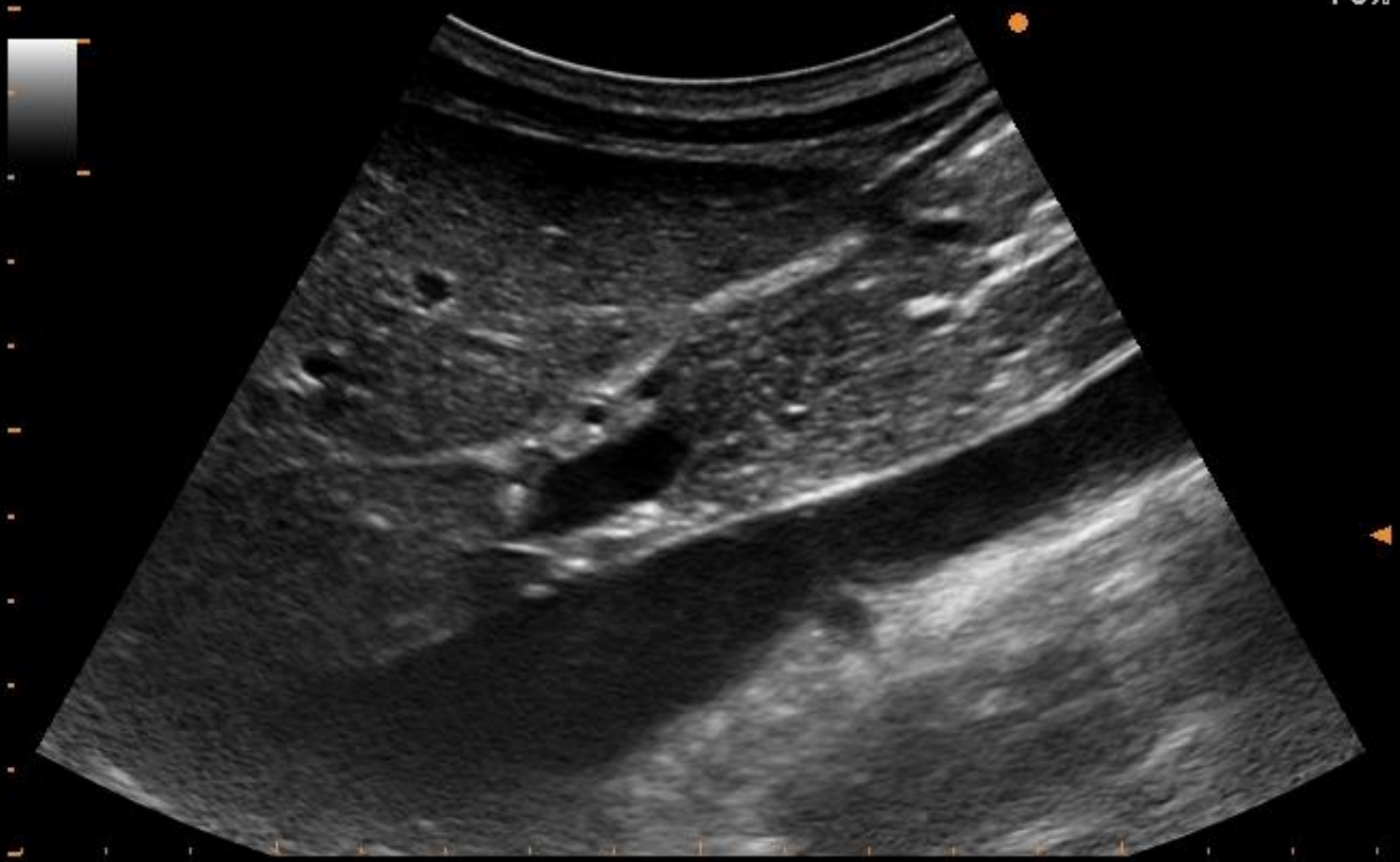


ALOKA A.Z. ST- LUCAS  
GENT

[Redacted]

15/09/22  
10:01:20

70%

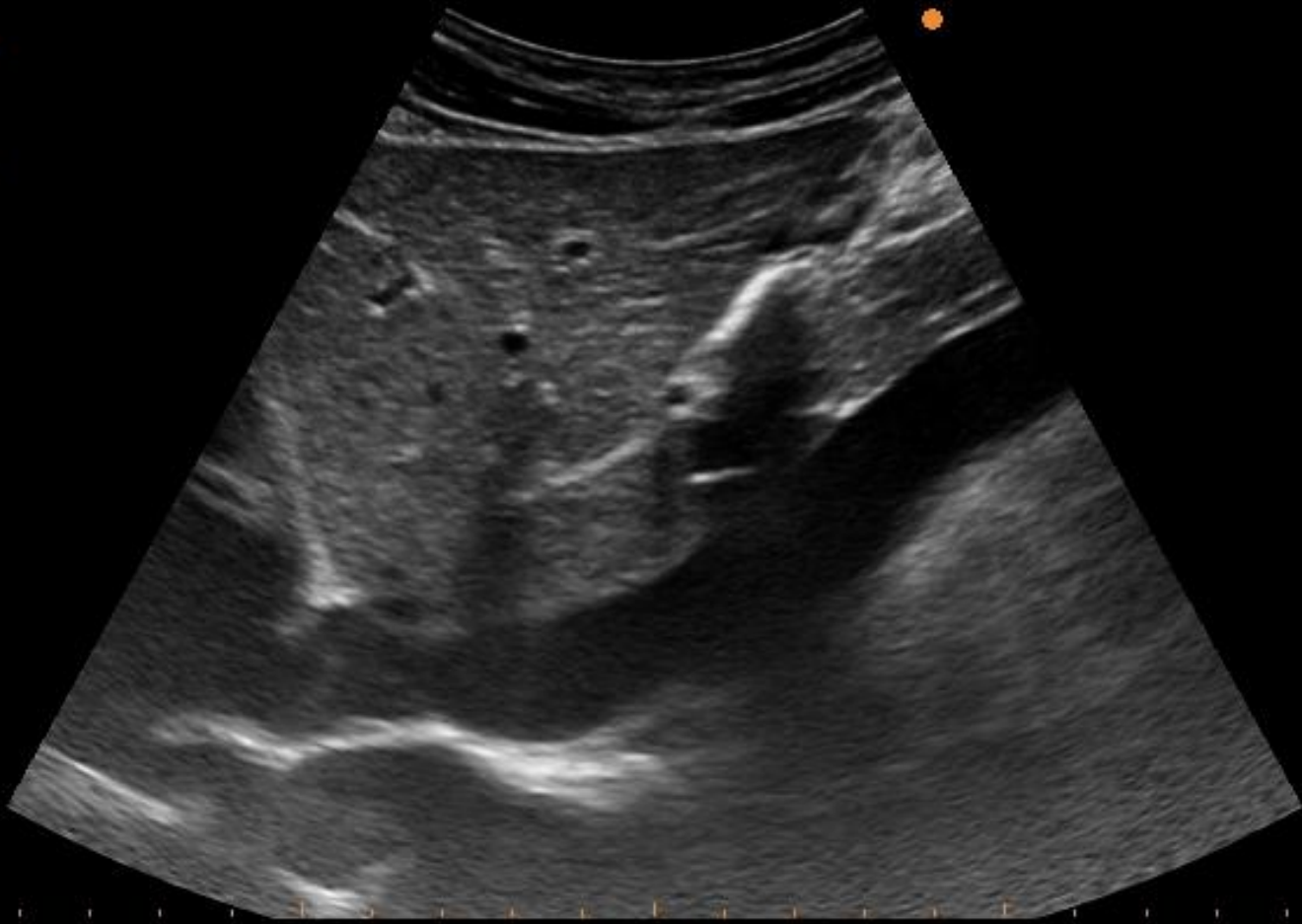


ALOKA A.Z. ST- LUCAS  
GENT

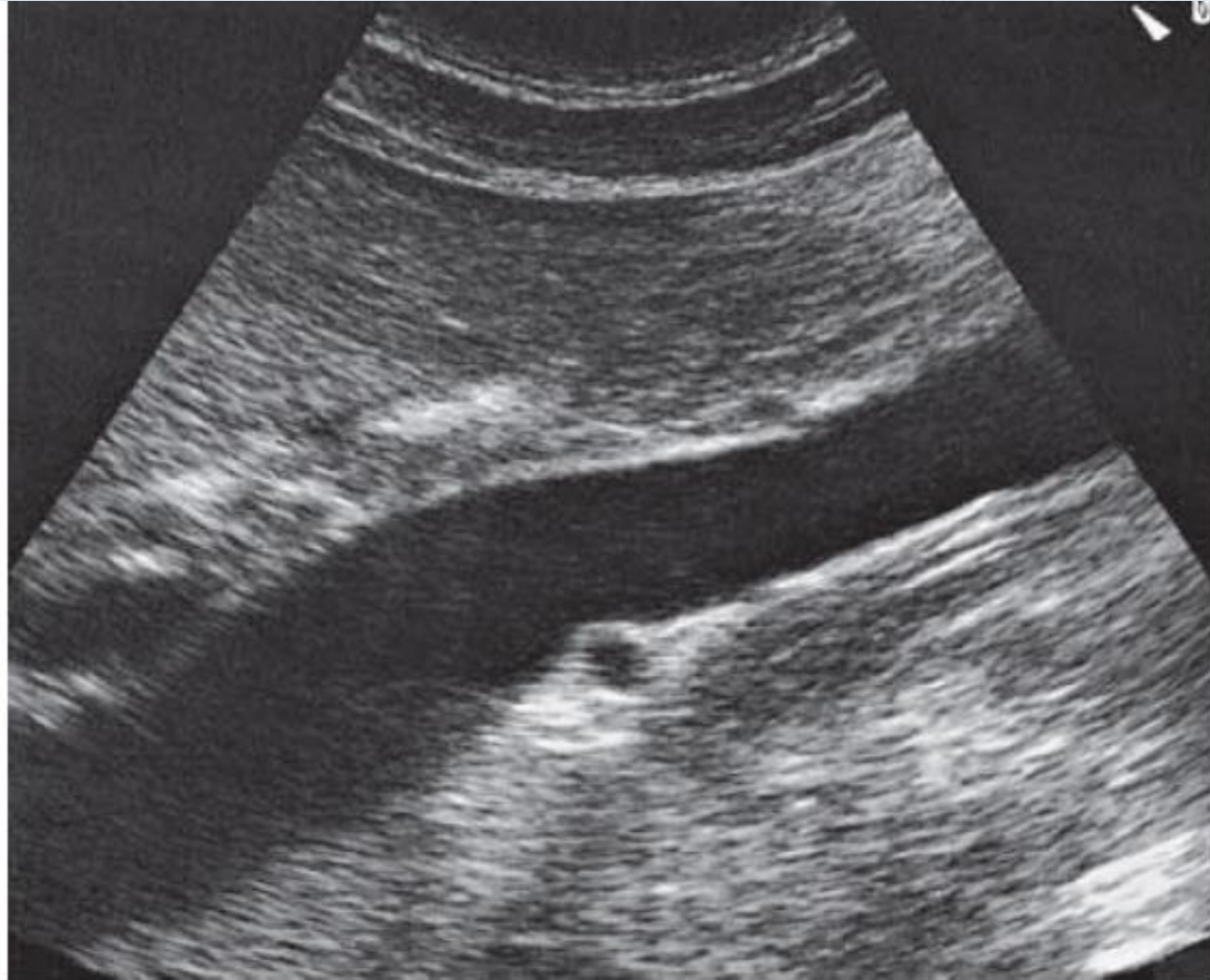
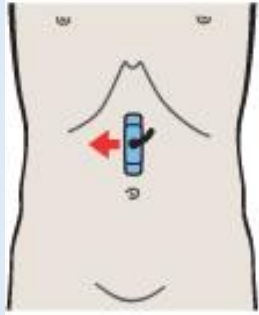
[Redacted]

15/09/22  
10:51:57

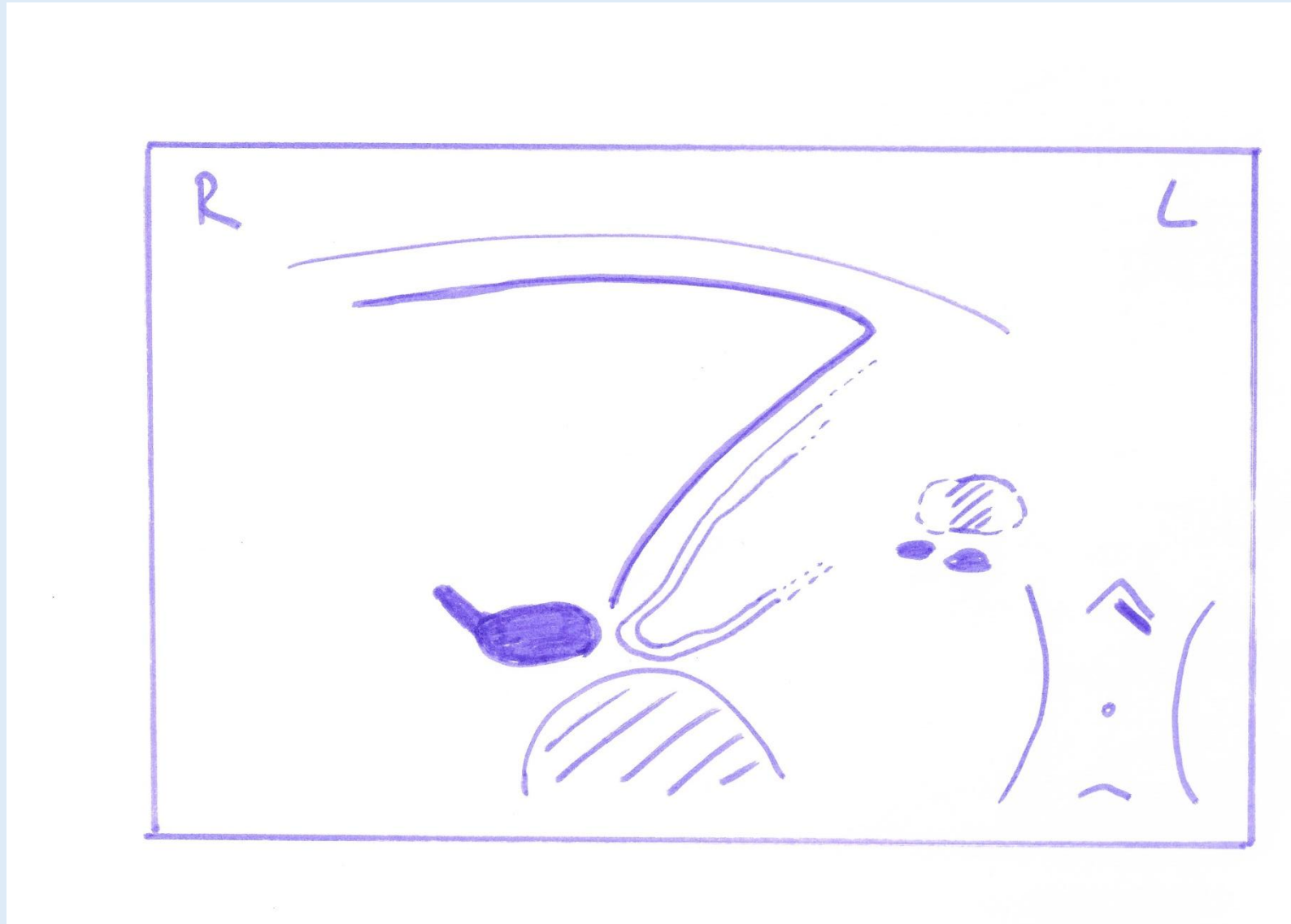
70%



# Vena cava inferior (sagittaal)



Lever: linker kwab



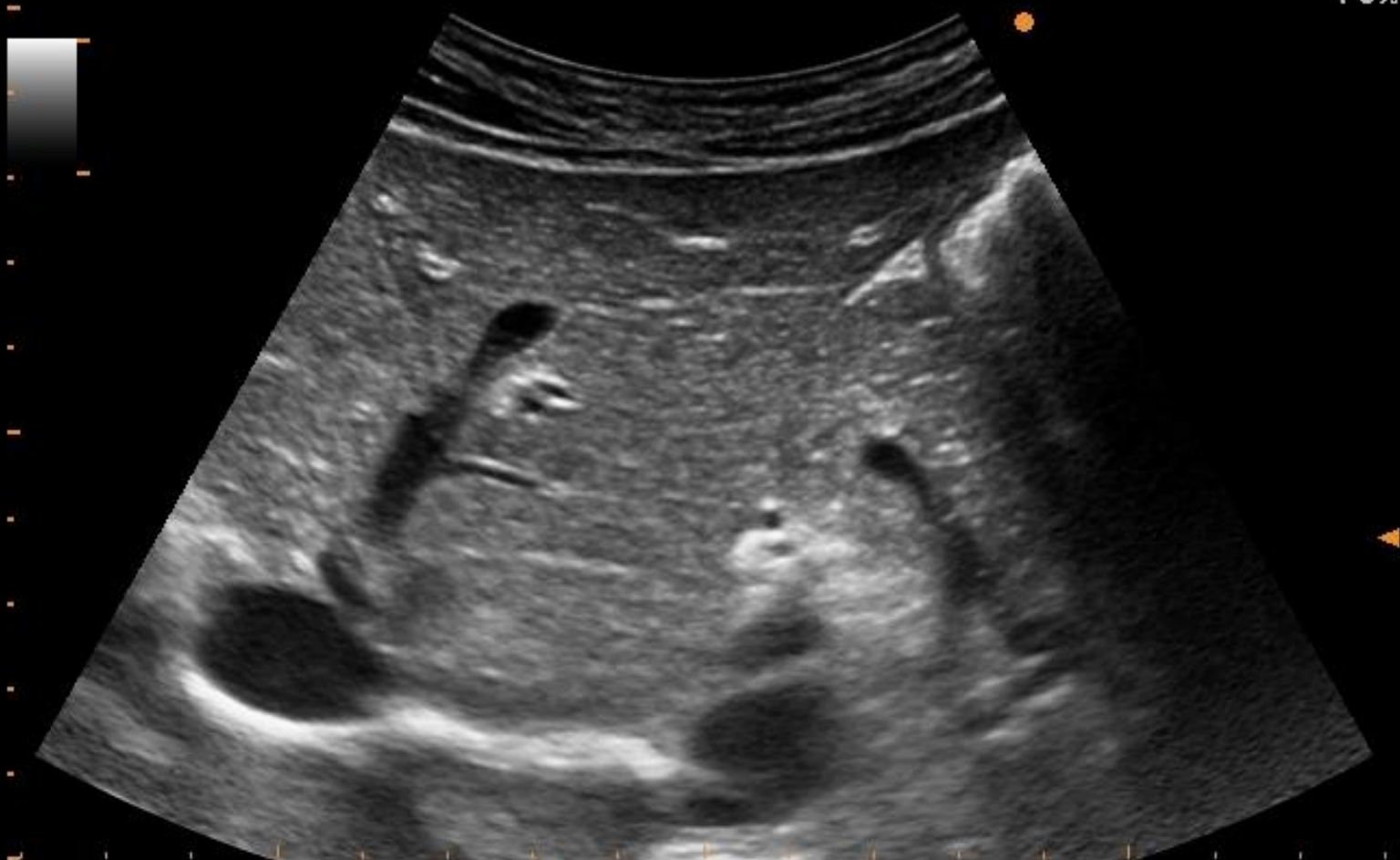ALOKA A.Z. ST- LUCAS  
GENT

[Redacted]

Y

15/09/22  
10:49:43

70%





ALOKA

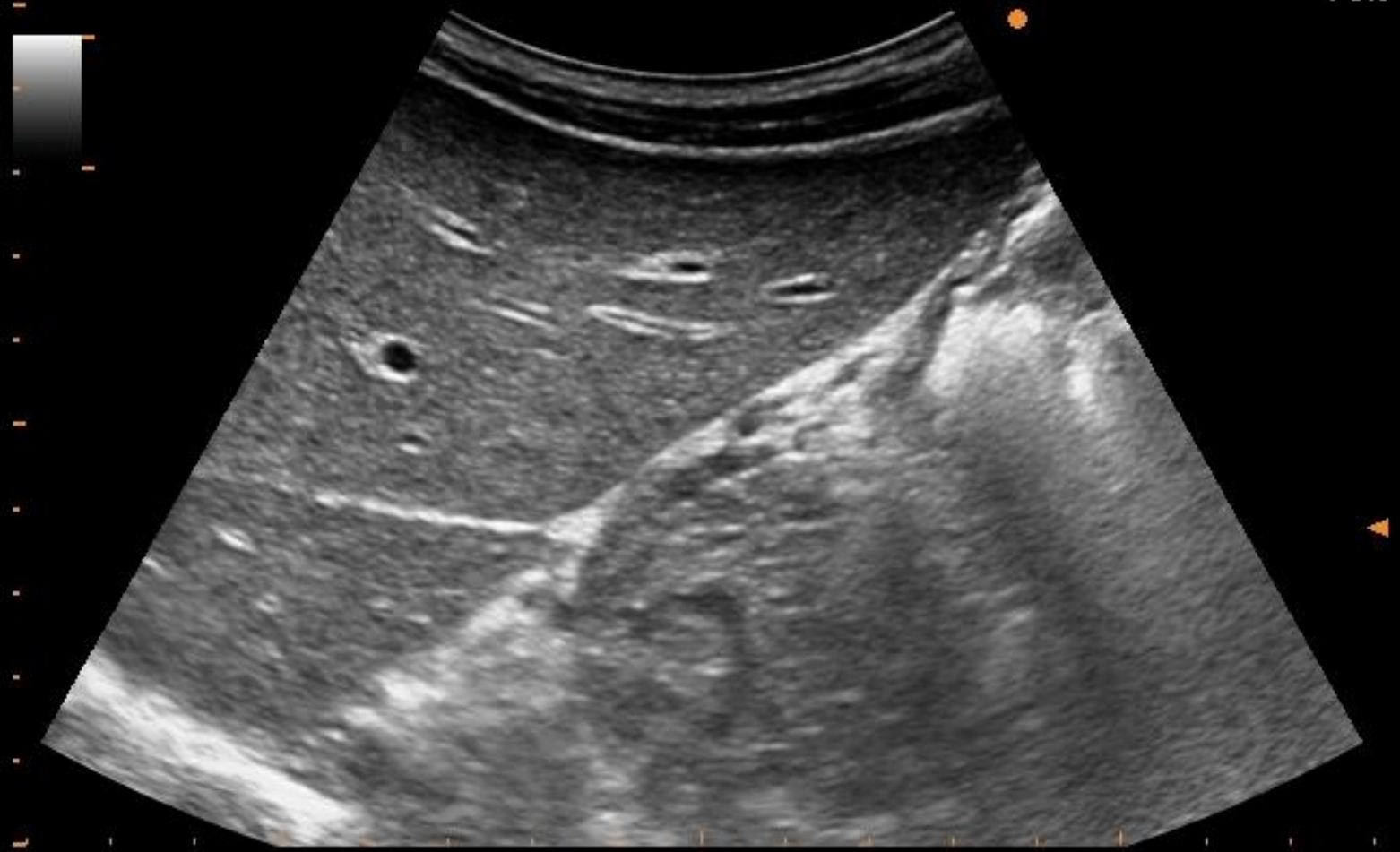
A.Z.  
GENT

ST- LUCAS

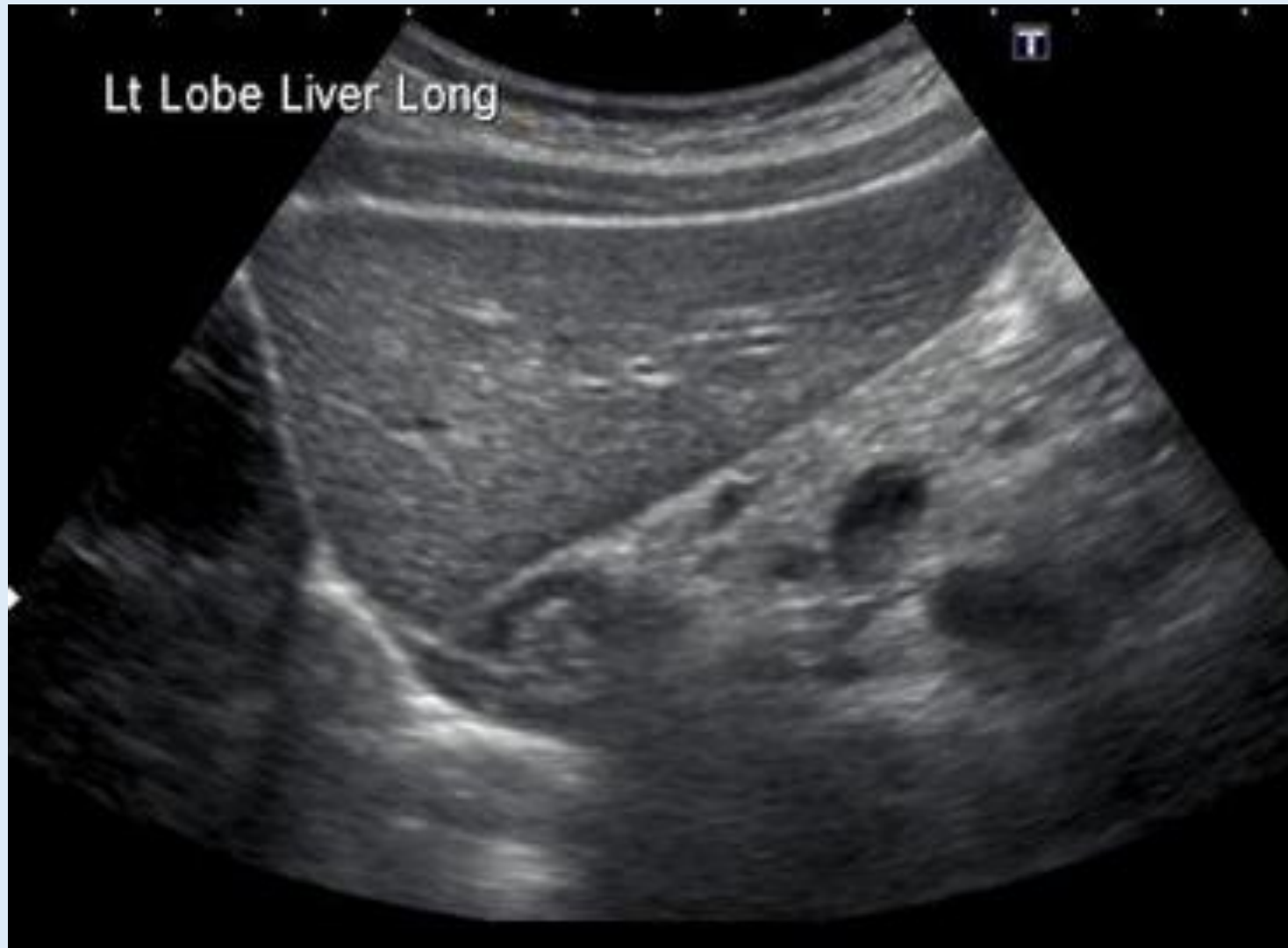: [REDACTED] Y

: 15/09/22  
09:52:42

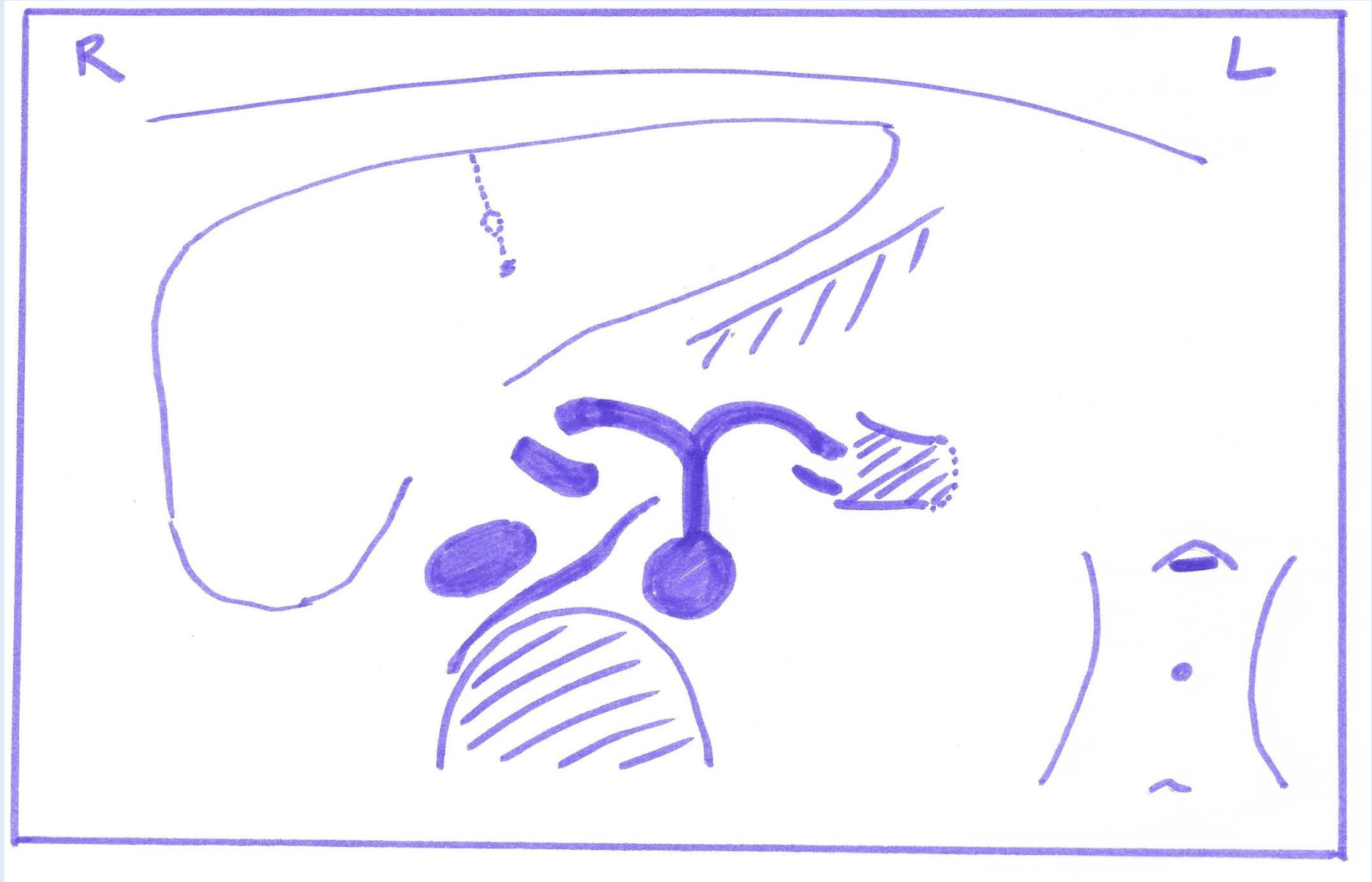
70%



Lever: linker kwab



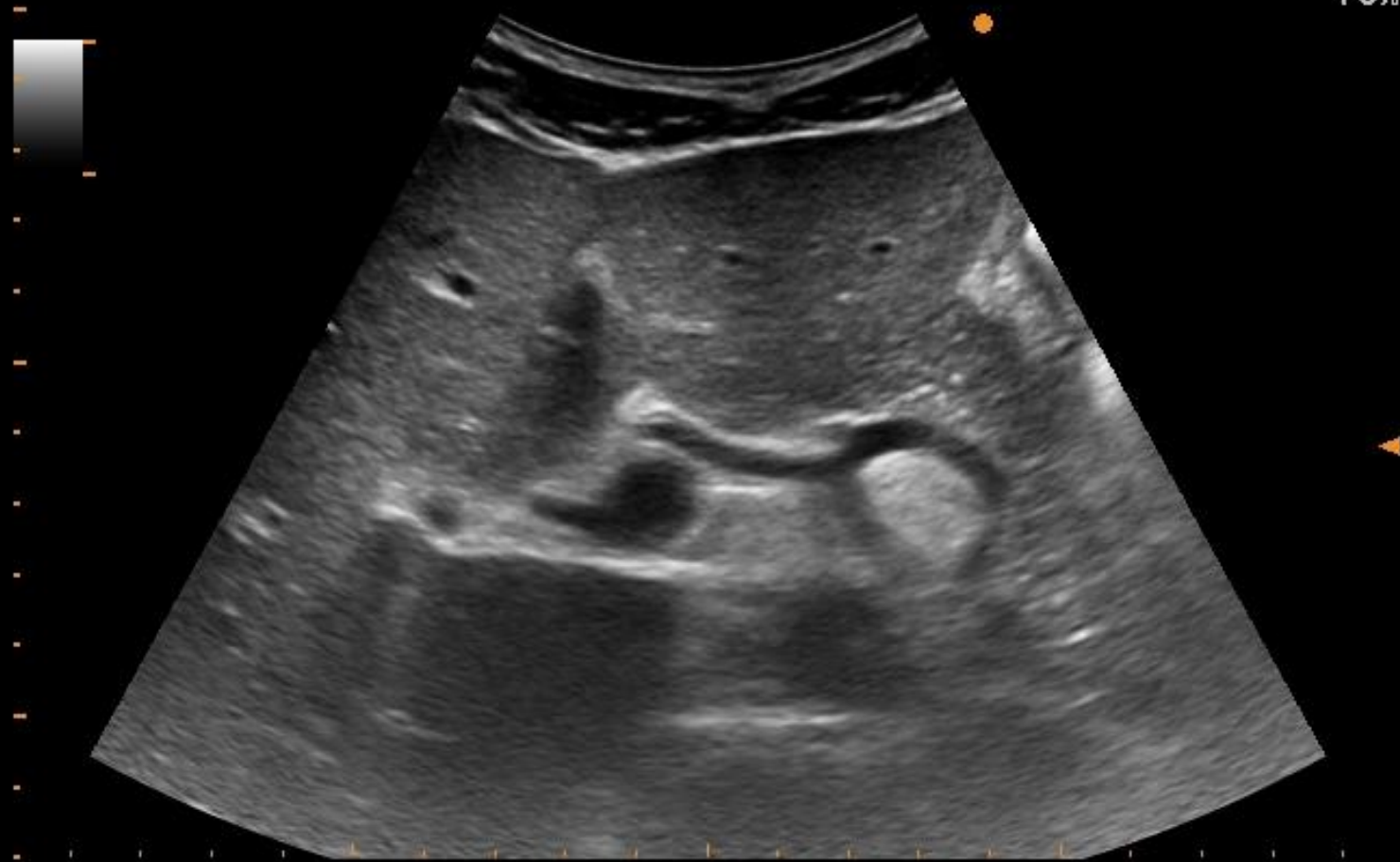Lever: Linker kwab + truncus



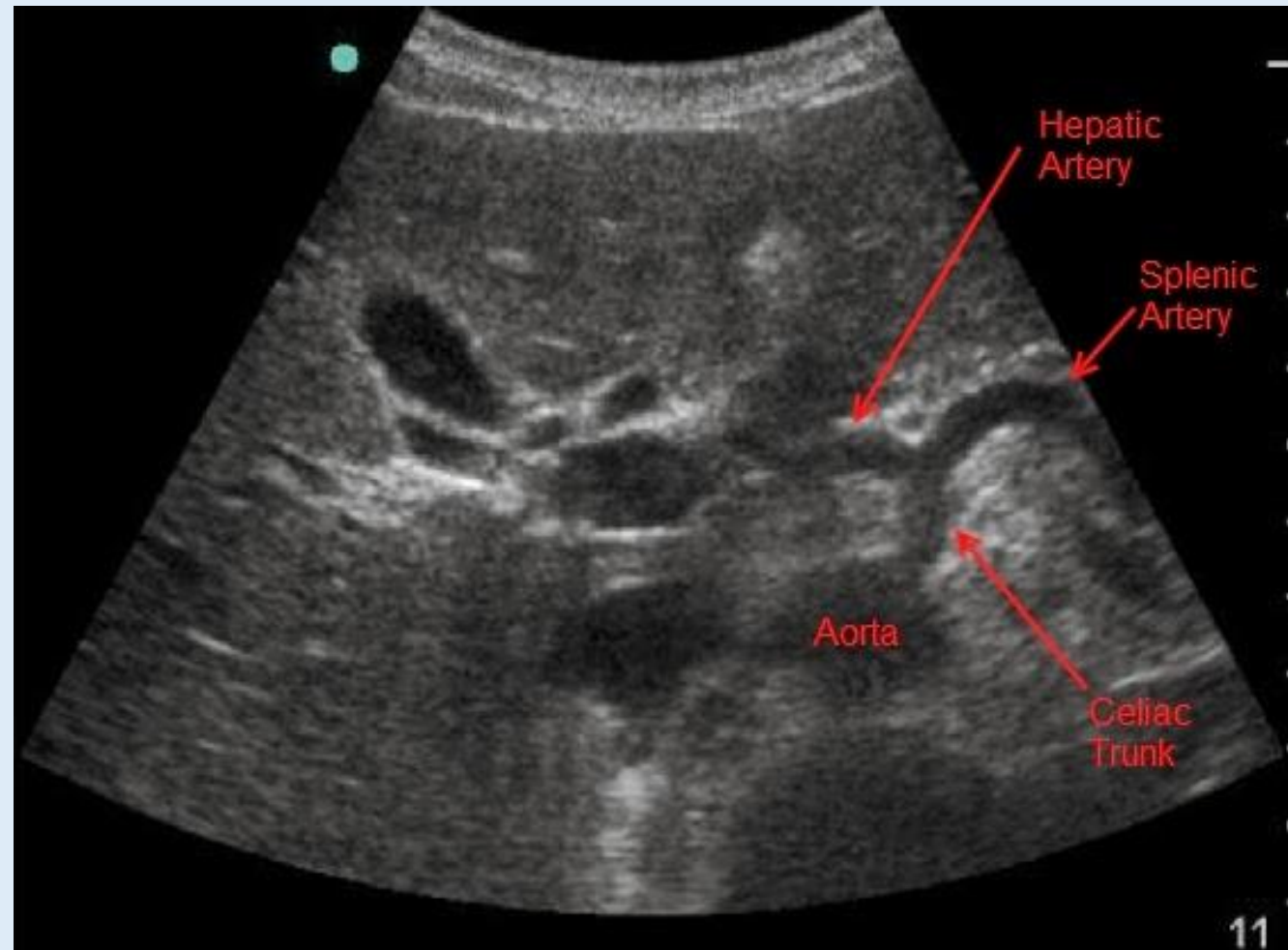
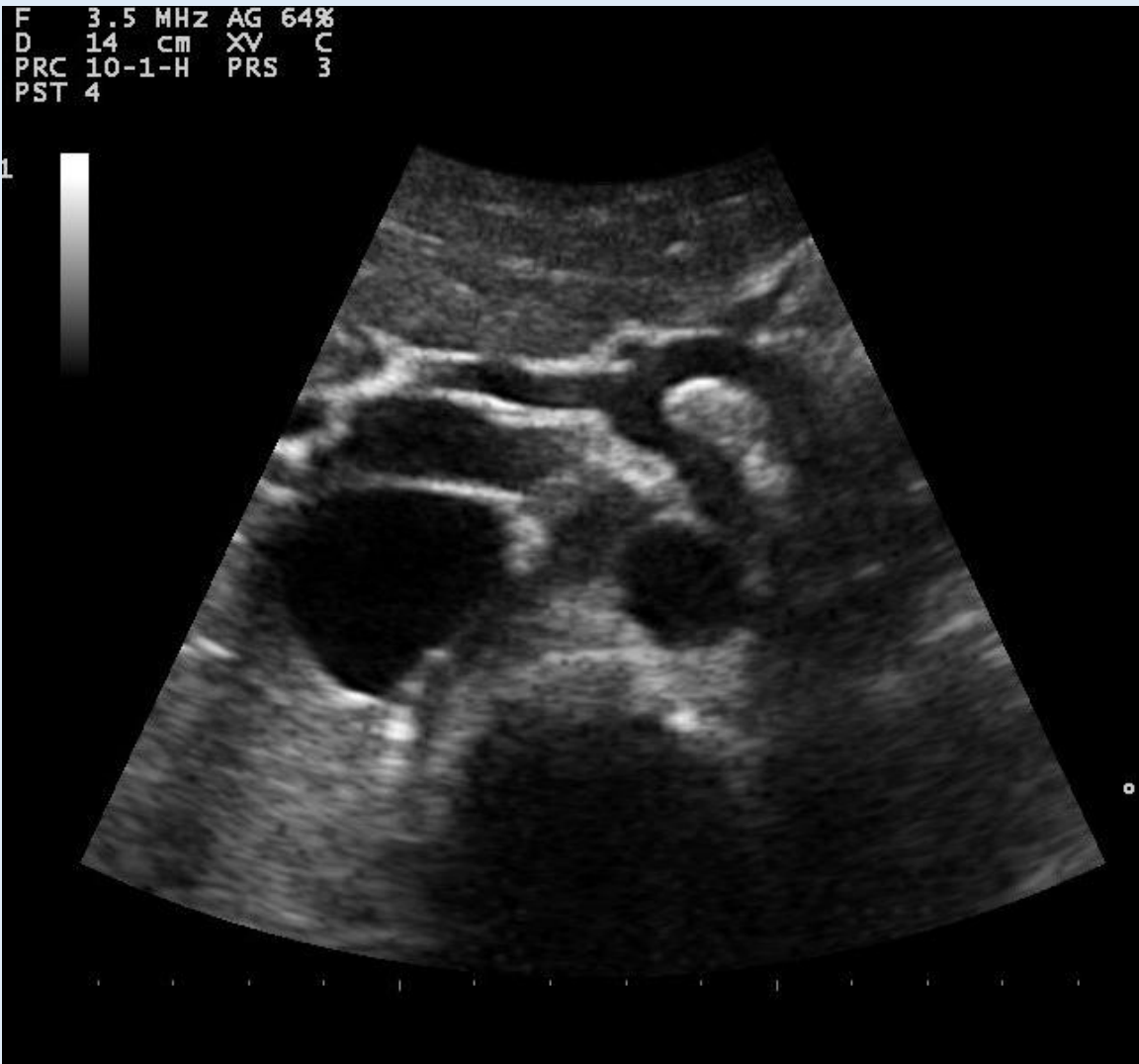ALOKA A.Z. ST- LUCAS  
GENT

15/09/22  
09:59:25

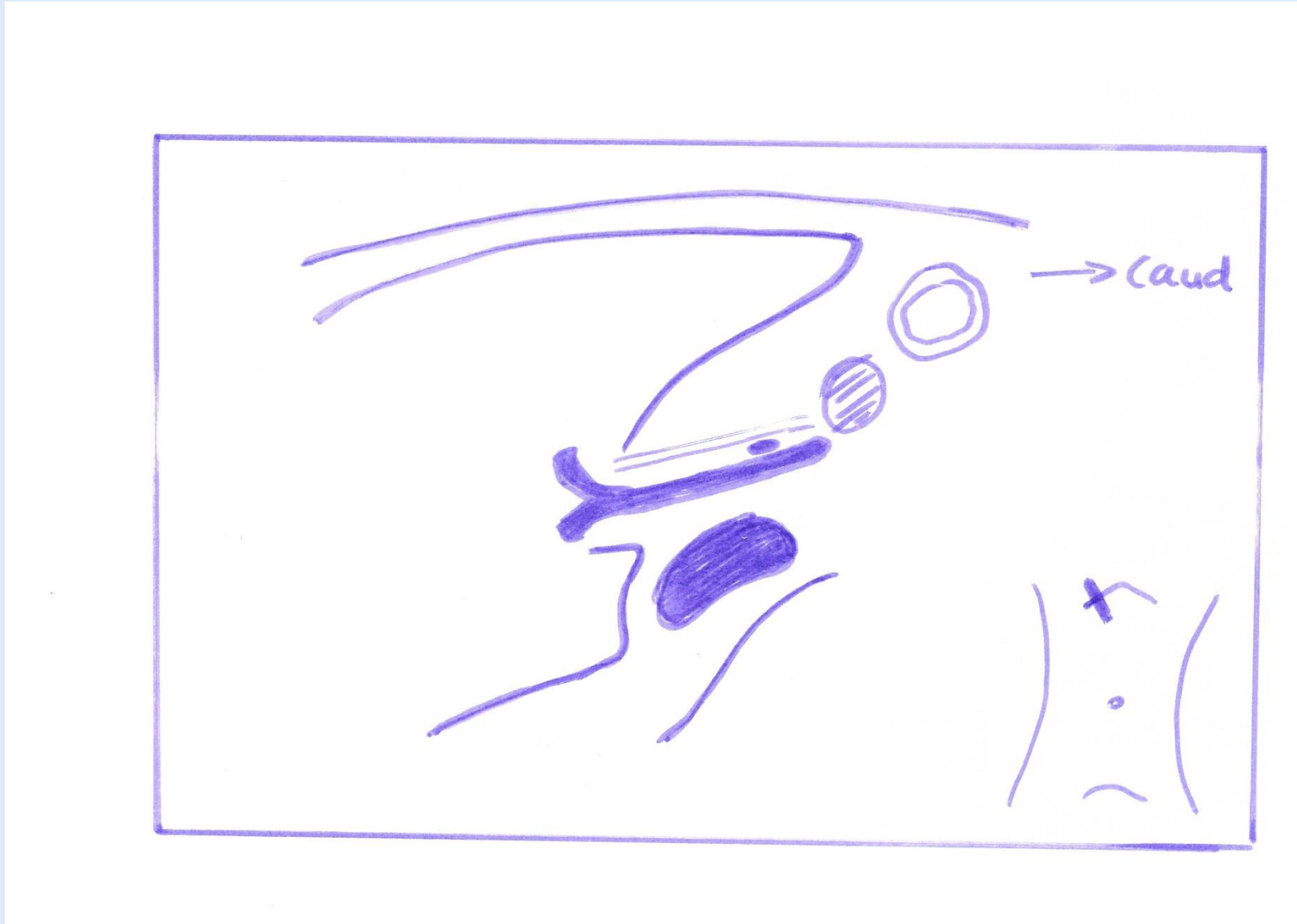
70%




# Lever: Linker kwab + truncus



# Liver: hilus



ALOKA A.Z. ST- LUCAS  
GENT


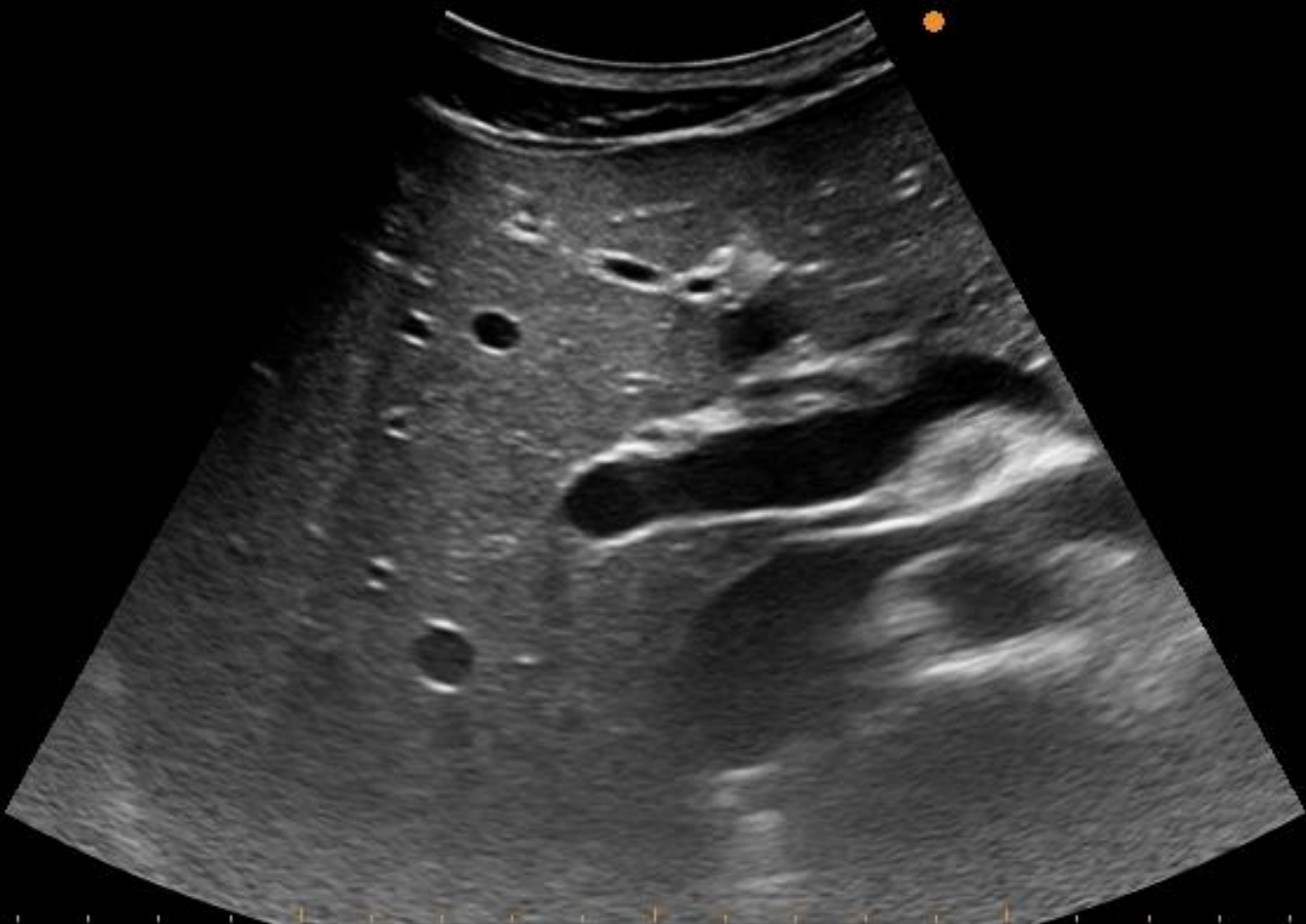


Y

:

15/09/22  
09:53:22

70%

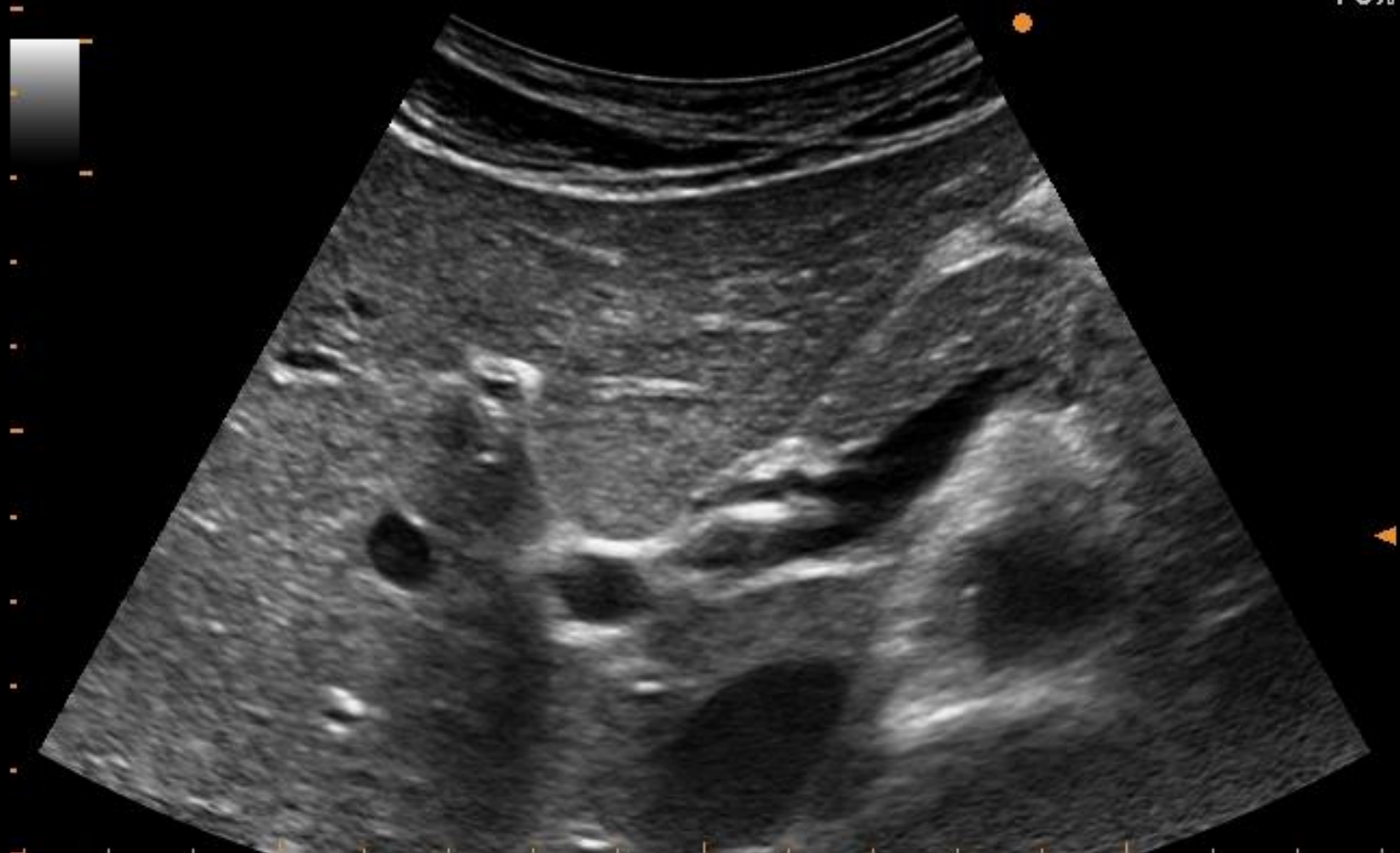


ALOKA A.Z. ST- LUCAS  
GENT

[Redacted]

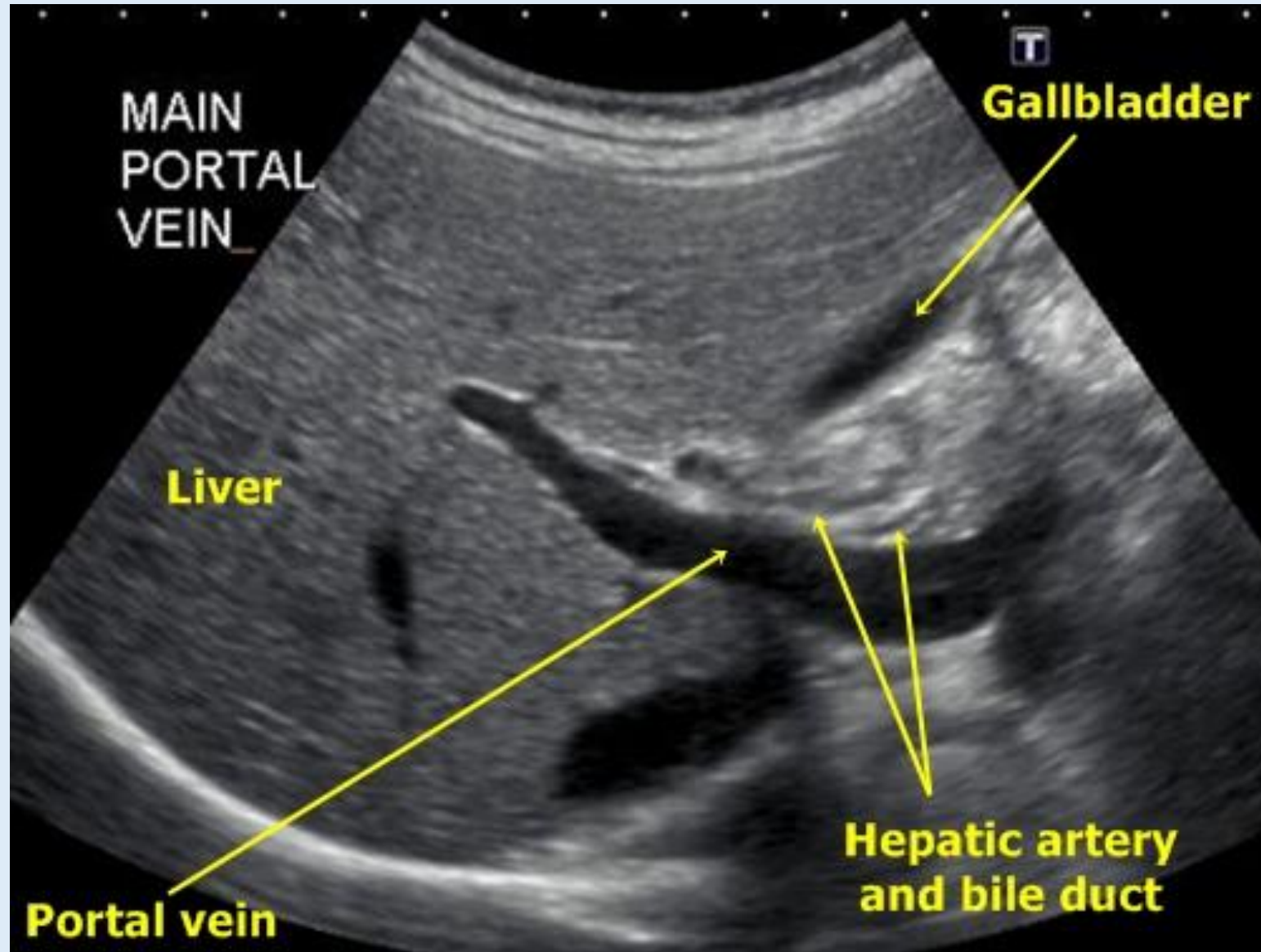
15/09/22  
10:50:16

70%

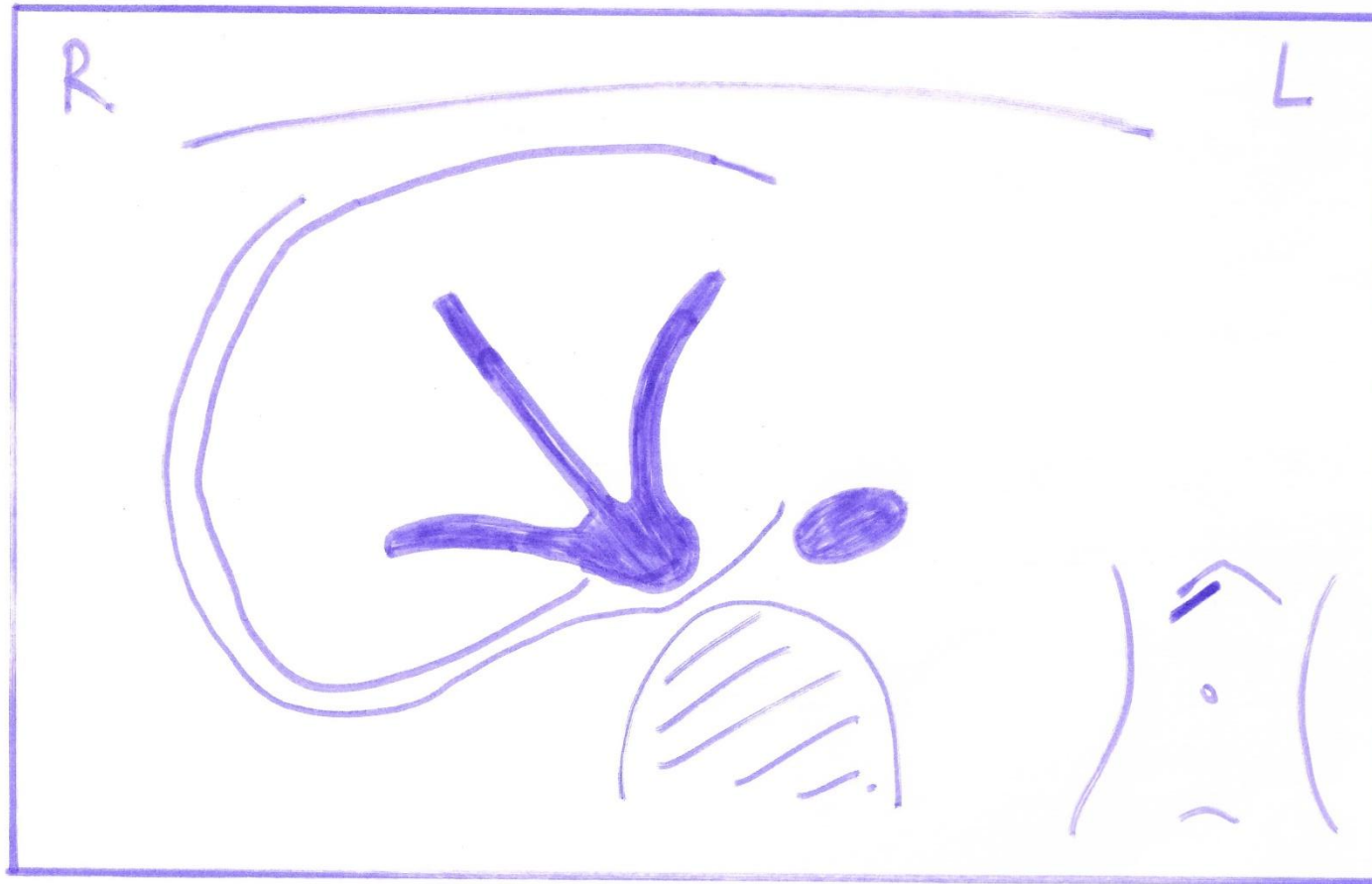




# Liver: hilus




# Lever: Rechter kwab – galblaas/galwegen



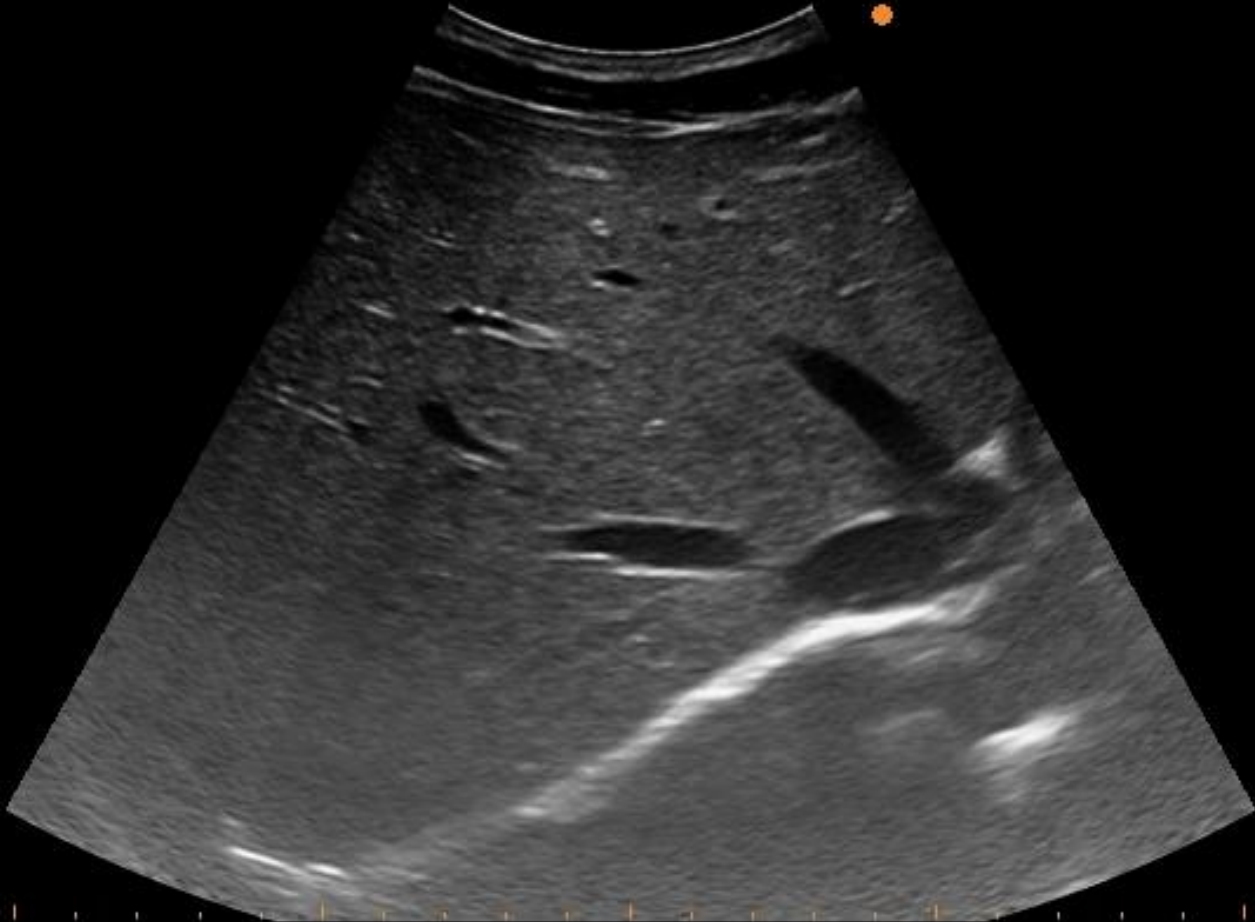
ALOKA

A.Z. ST- LUCAS  
GENT



15/09/22  
09:53:49

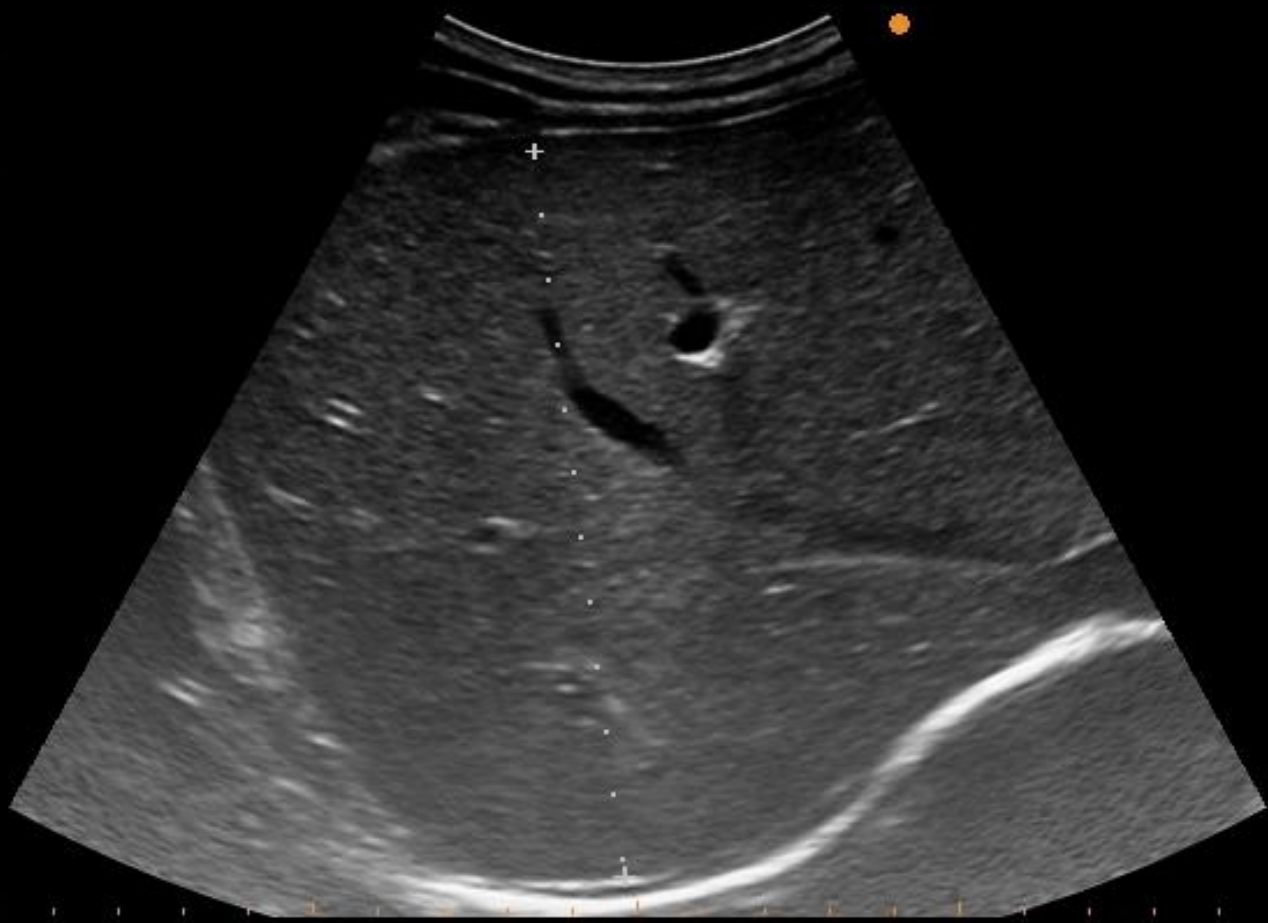
70%



ALOKA A.Z. ST- LUCAS  
GENT

15/09/22  
09:54:36

70%

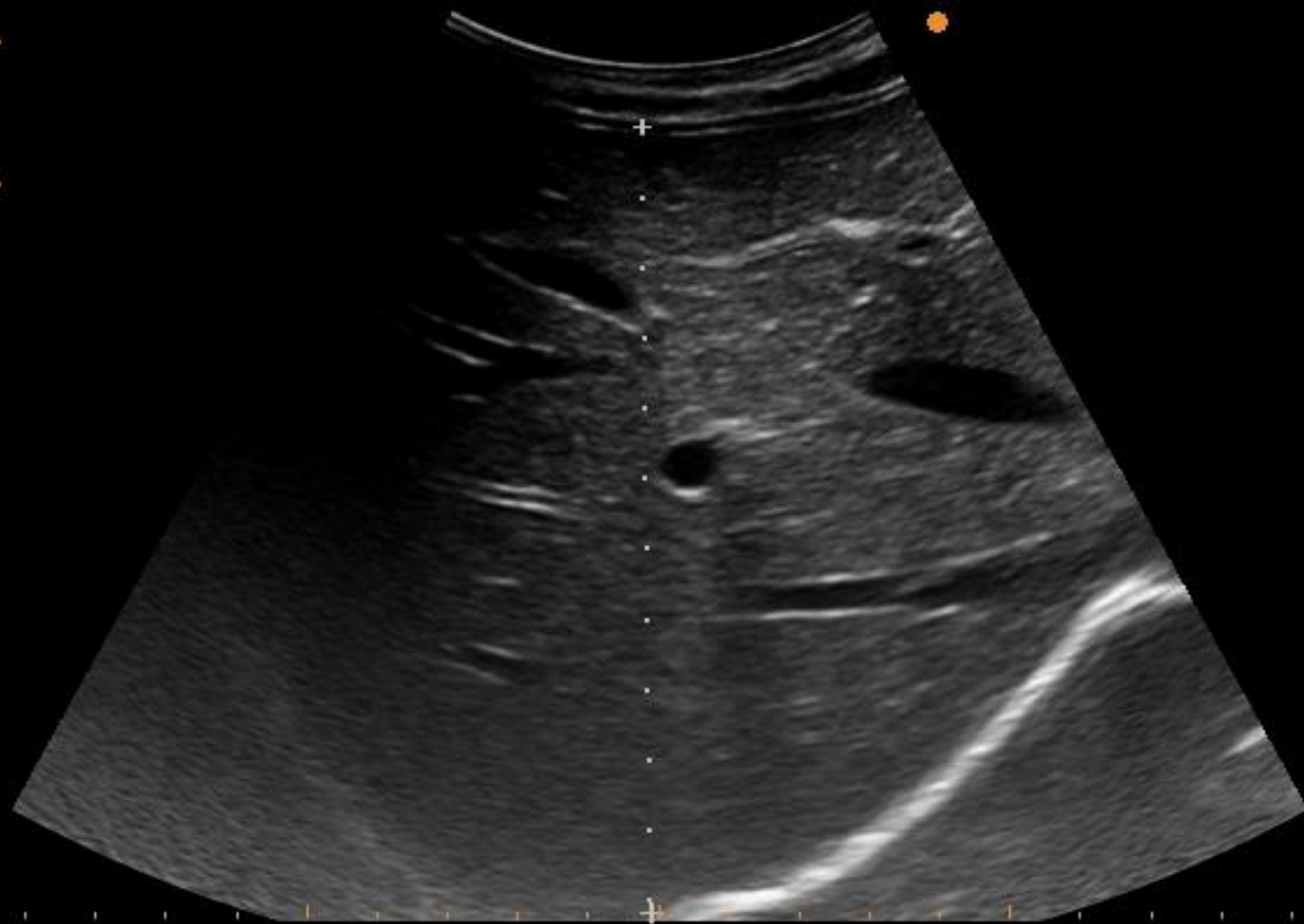

Dist: 113mm

ALOKA A.Z. ST- LUCAS  
GENT

15/09/22  
10:51:04

70%



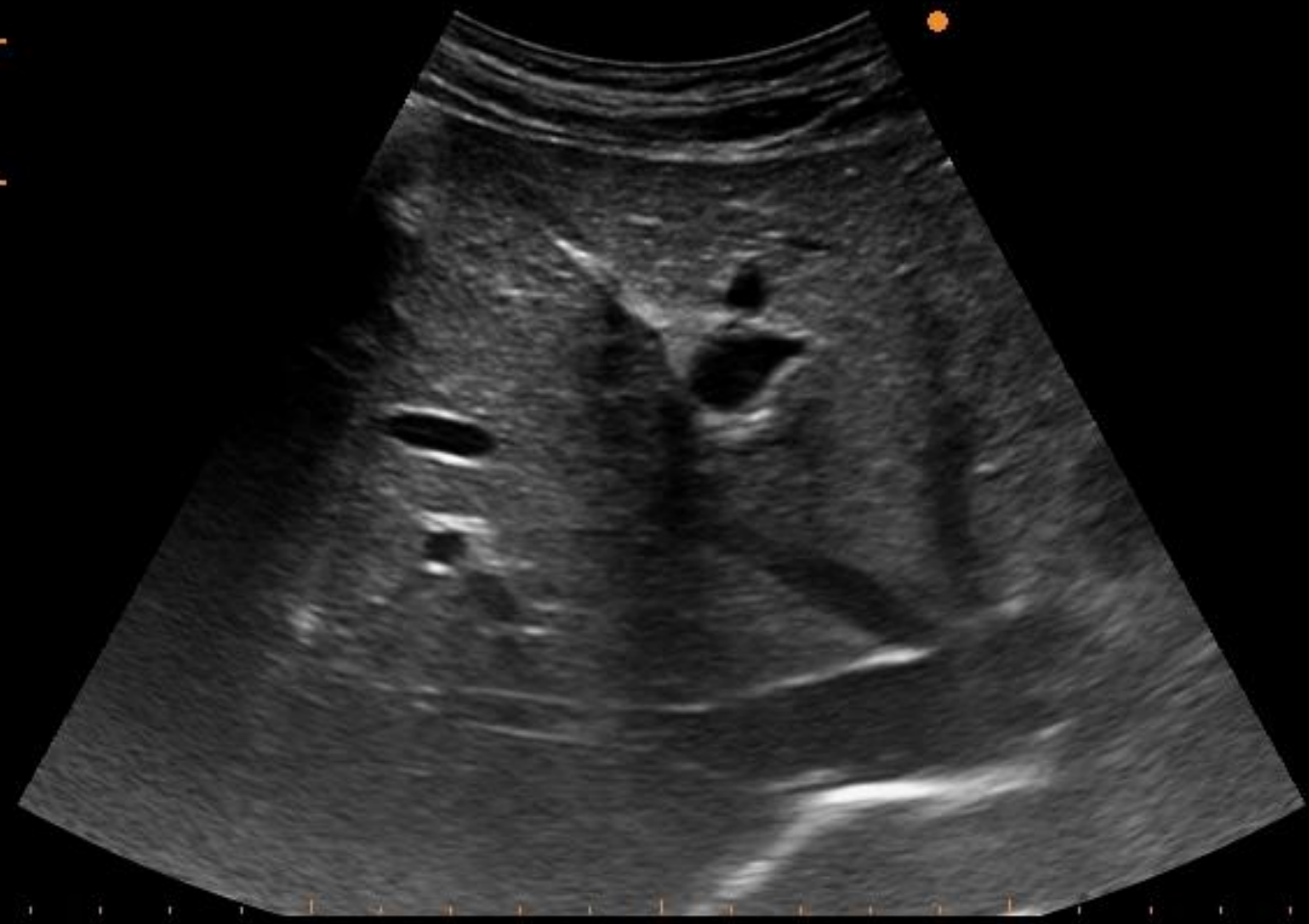Dist: 112mm

ALOKA A.Z. ST- LUCAS  
GENT

[Redacted]

15/09/22  
10:51:29

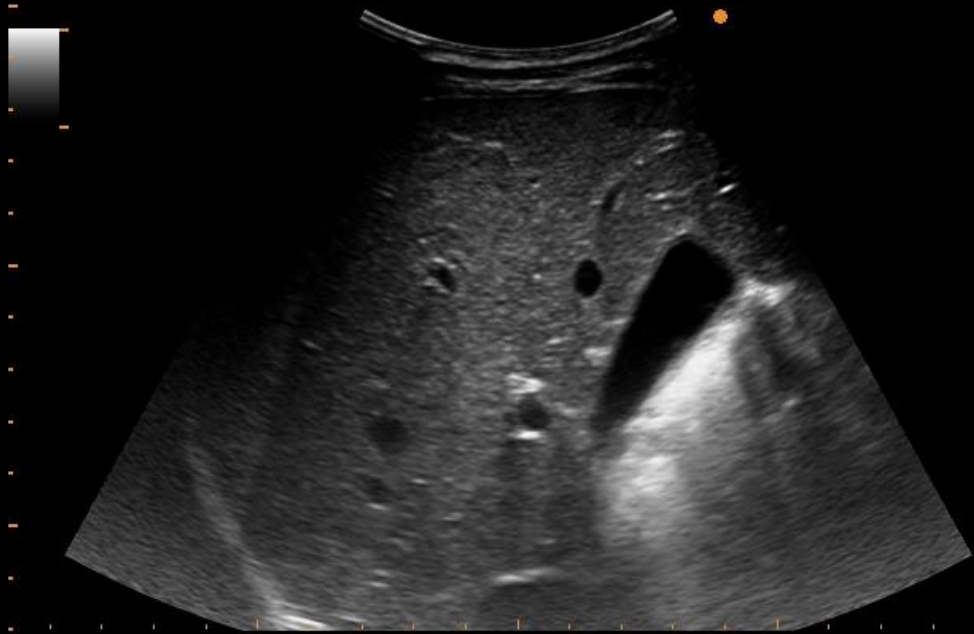
70%



ALOKA A.Z. ST- LUCAS  
GENT

15/09/22  
10:54:09

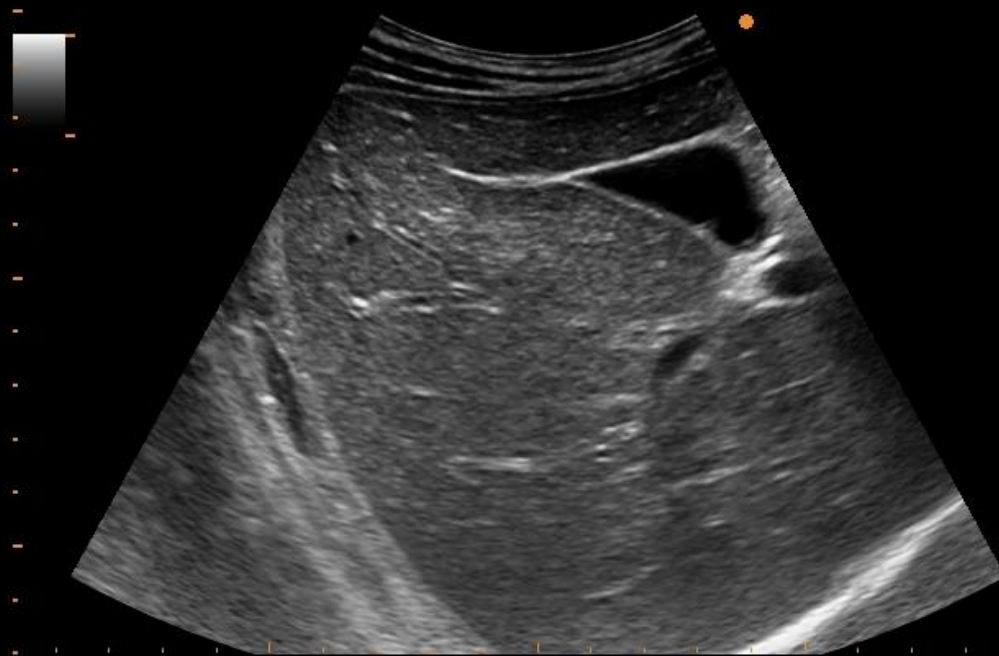
70%



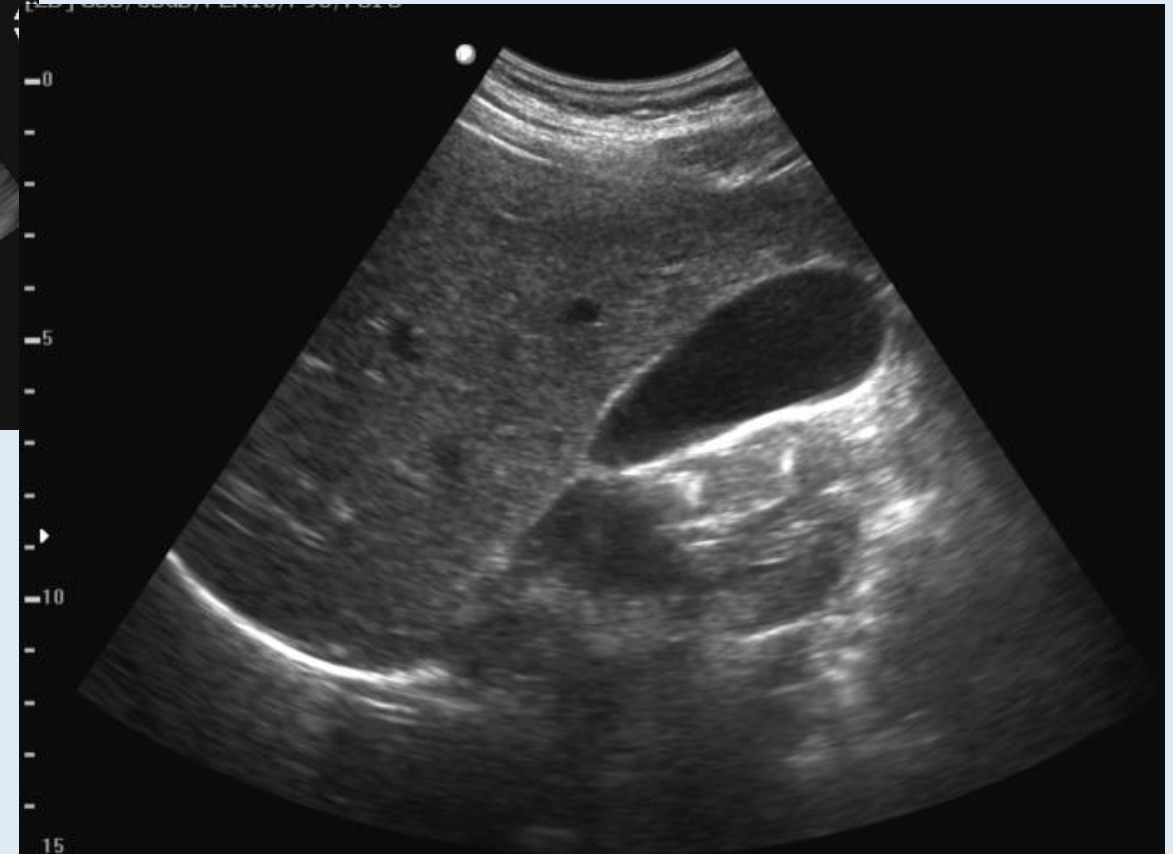
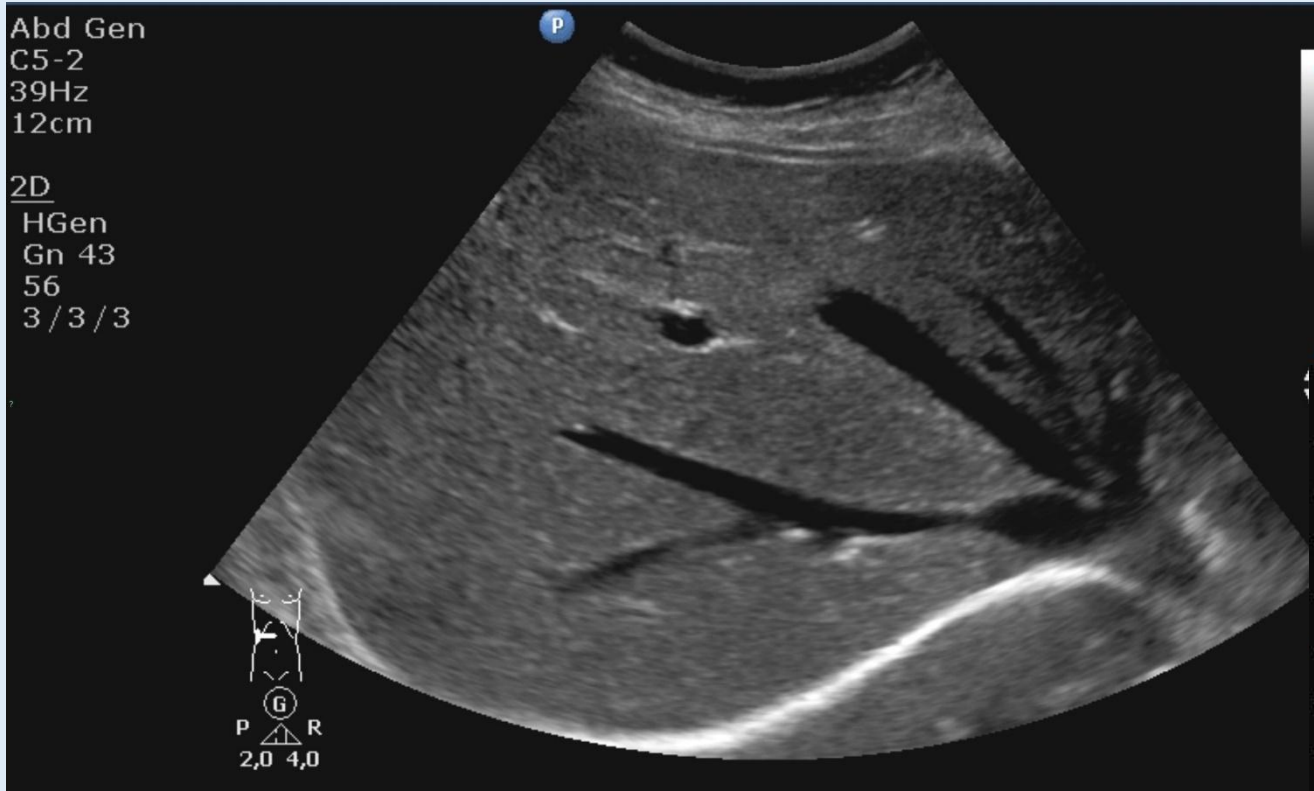ALOKA A.Z. ST- LUCAS  
GENT

15/09/22  
10:54:35

70%

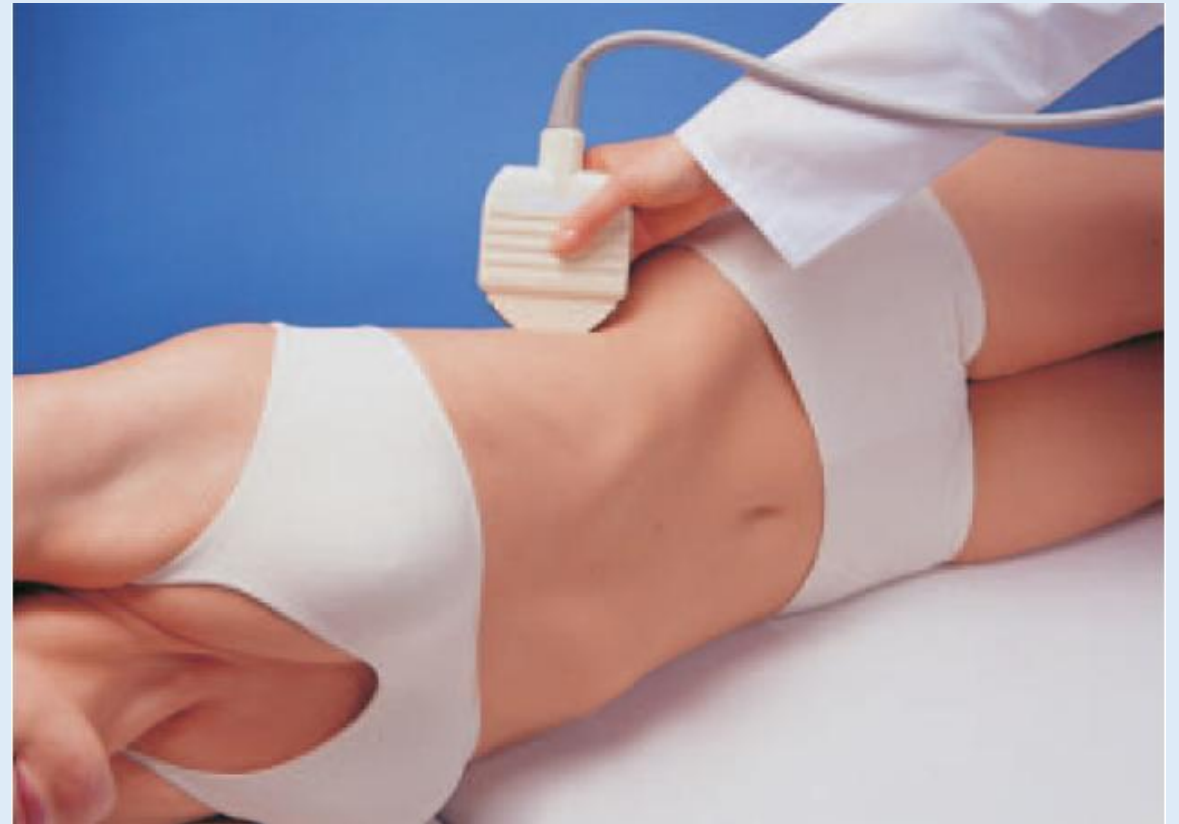
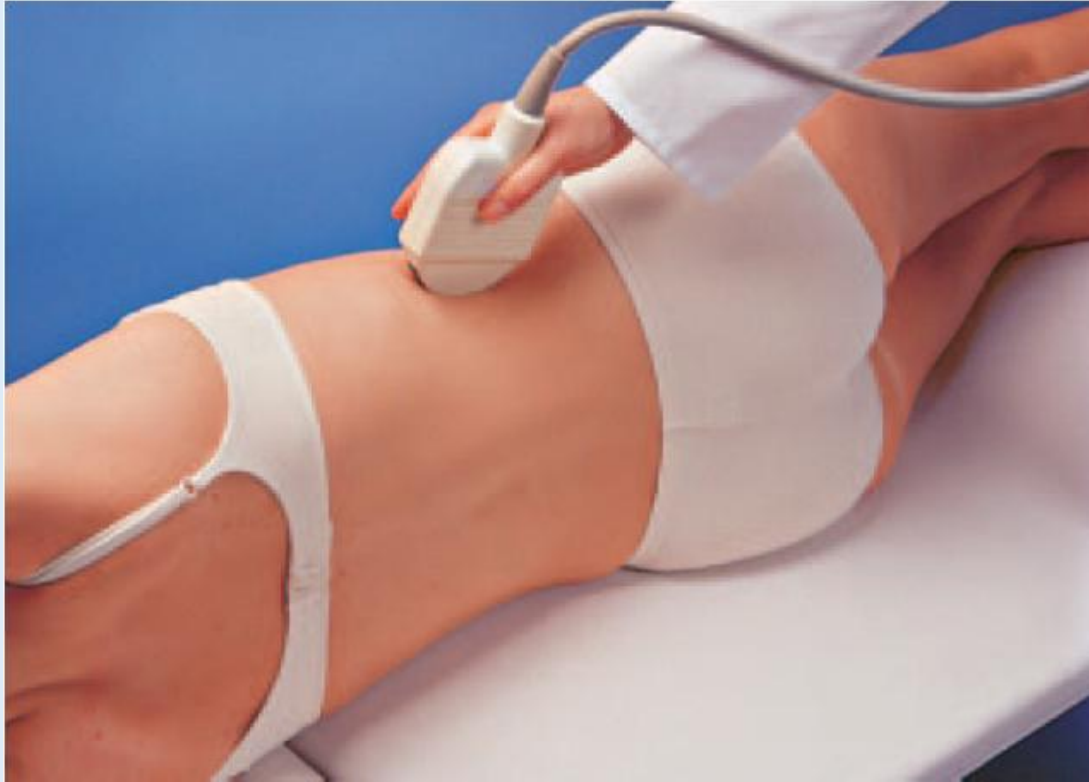

# Lever: Rechter kwab – galblaas/galwegen





# Nieren – milt - pancreasstaart



ALOKA A.Z. ST- LUCAS  
GENT

15/09/22  
09:55:50

70%

Dist: 96mm

ALOKA A.Z. ST- LUCAS  
GENT

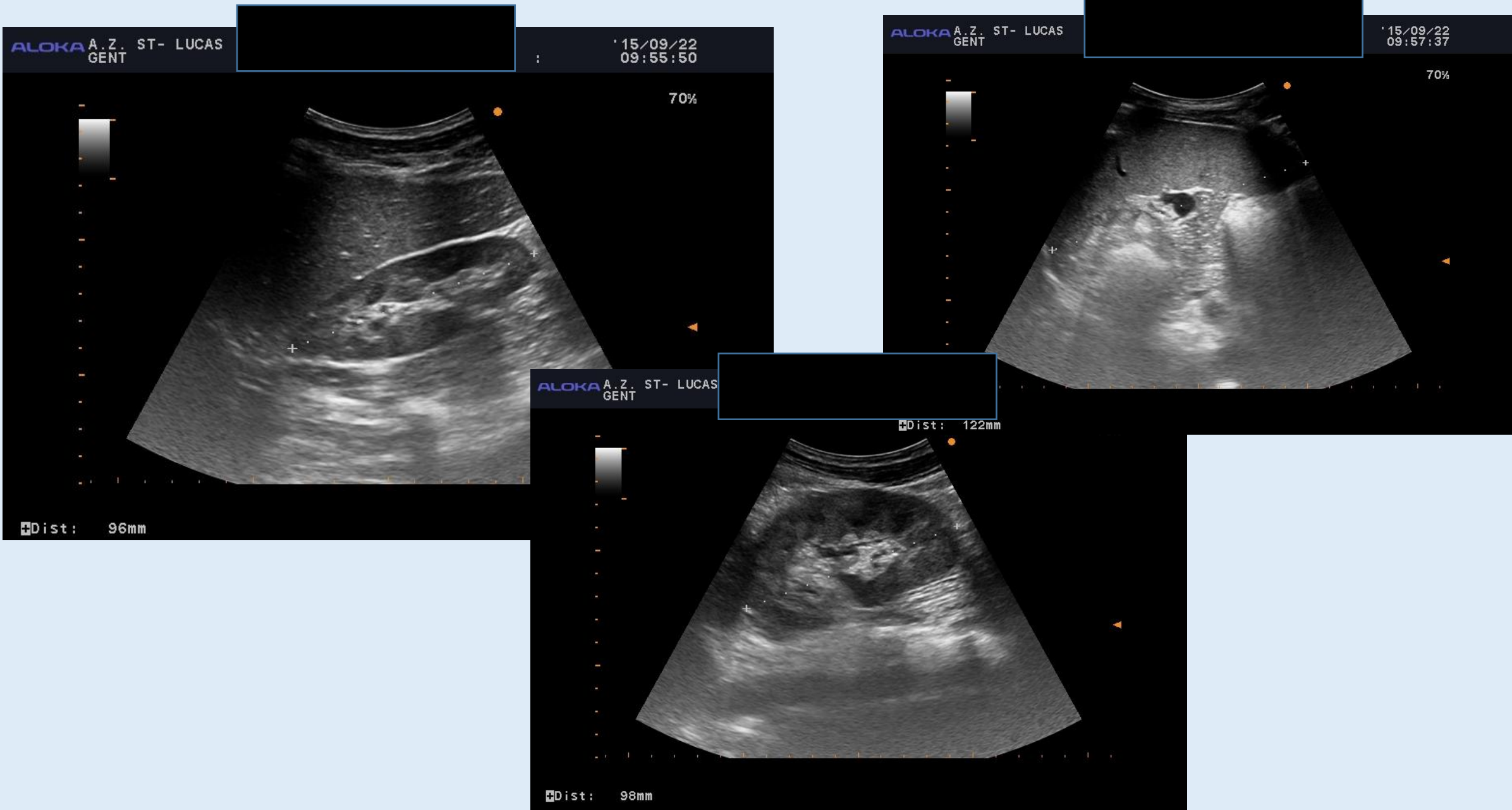
15/09/22  
09:57:37

70%

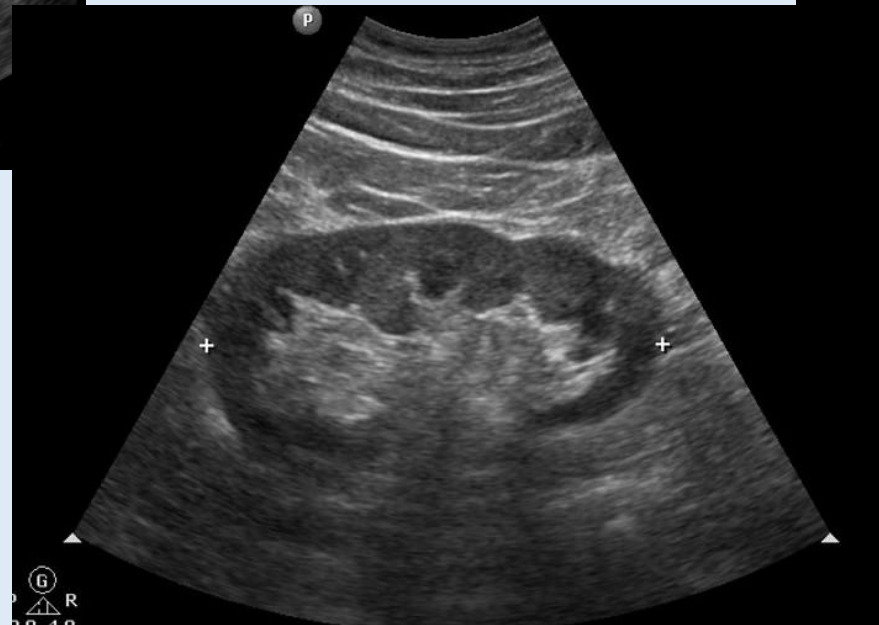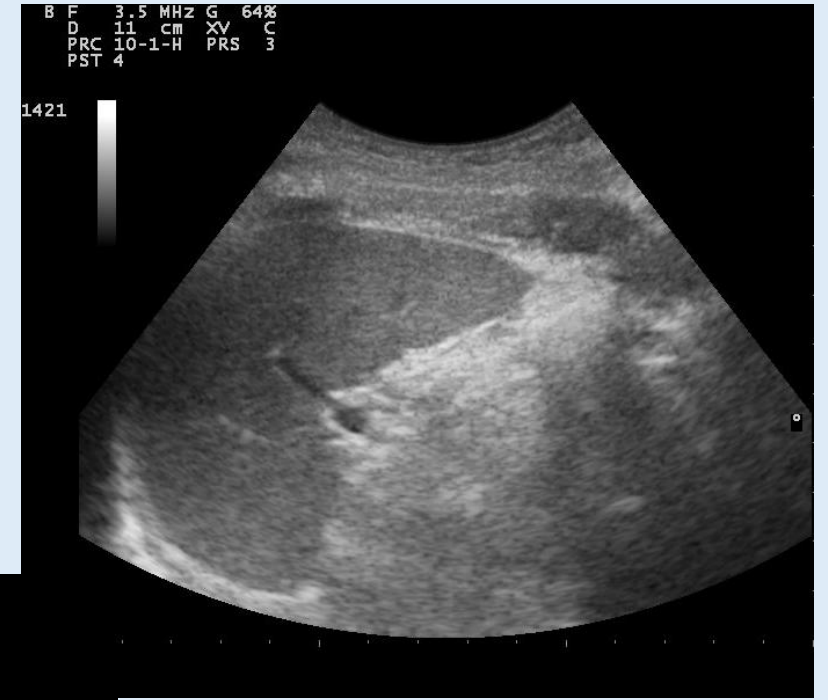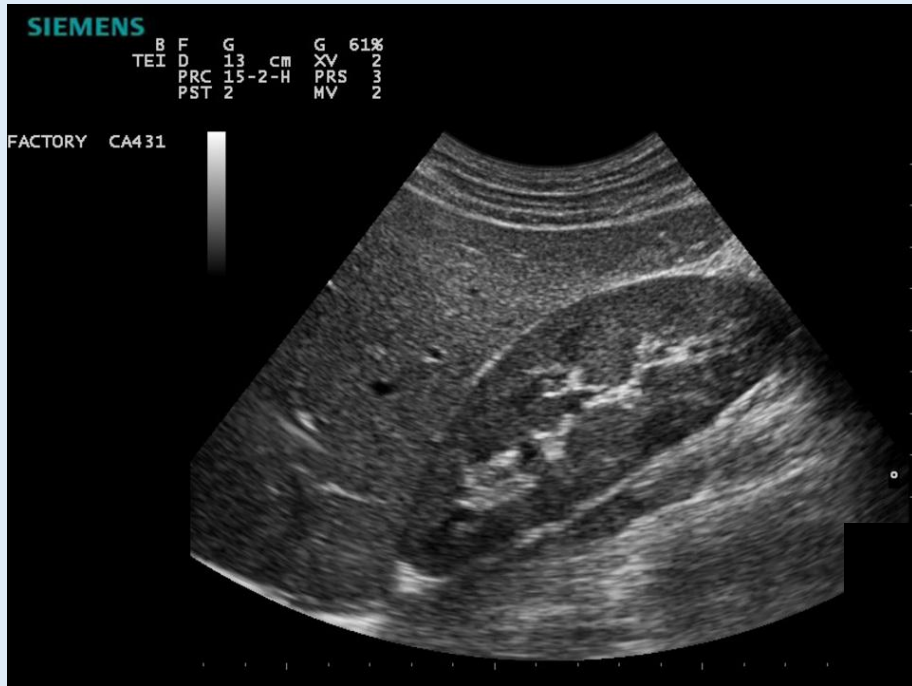
Dist: 122mm

ALOKA A.Z. ST- LUCAS  
GENT

Dist: 98mm



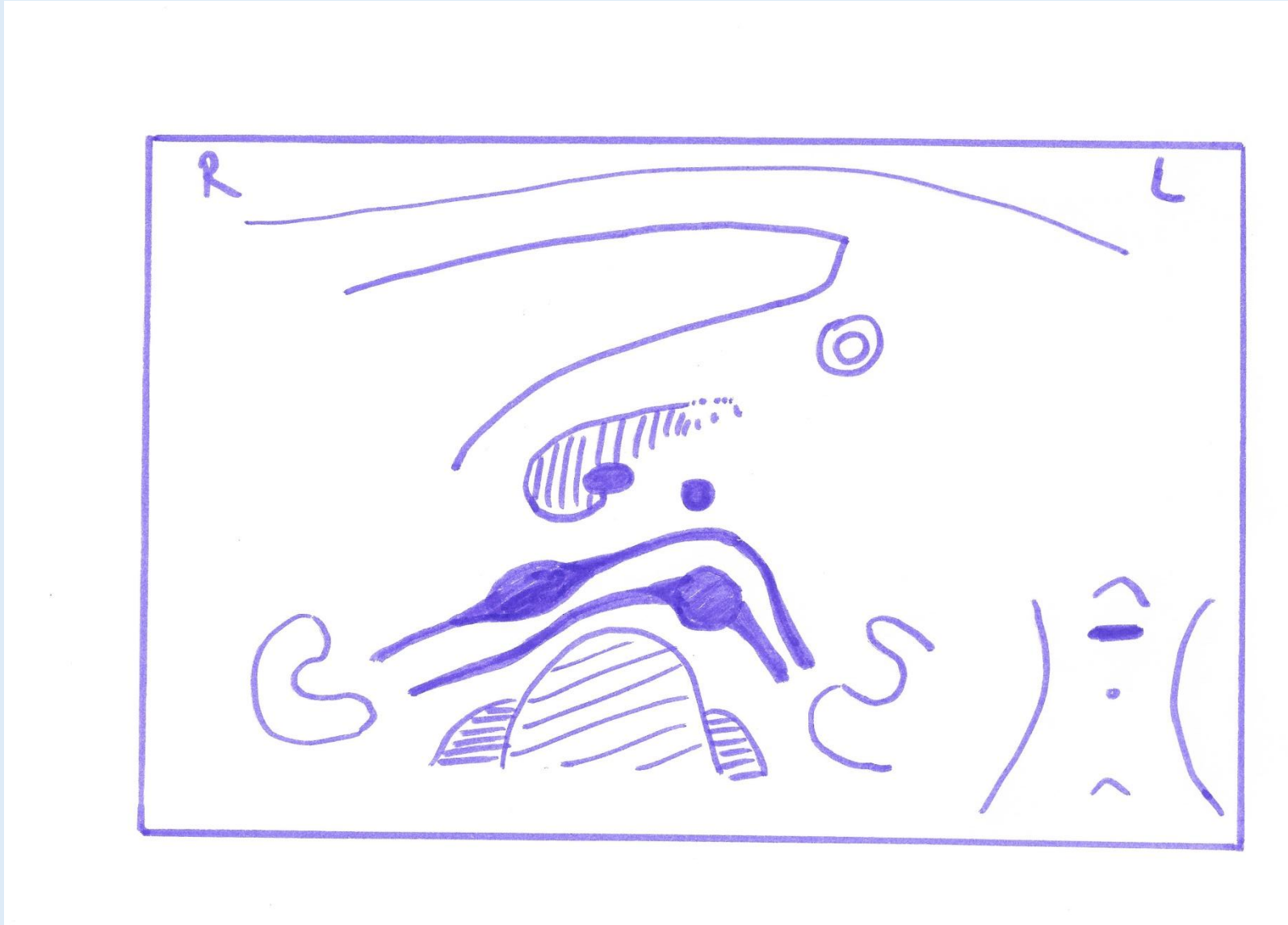
# Nieren – milt - pancreasstaart



# Pancreas – Aorta/vena cava (transversaal)



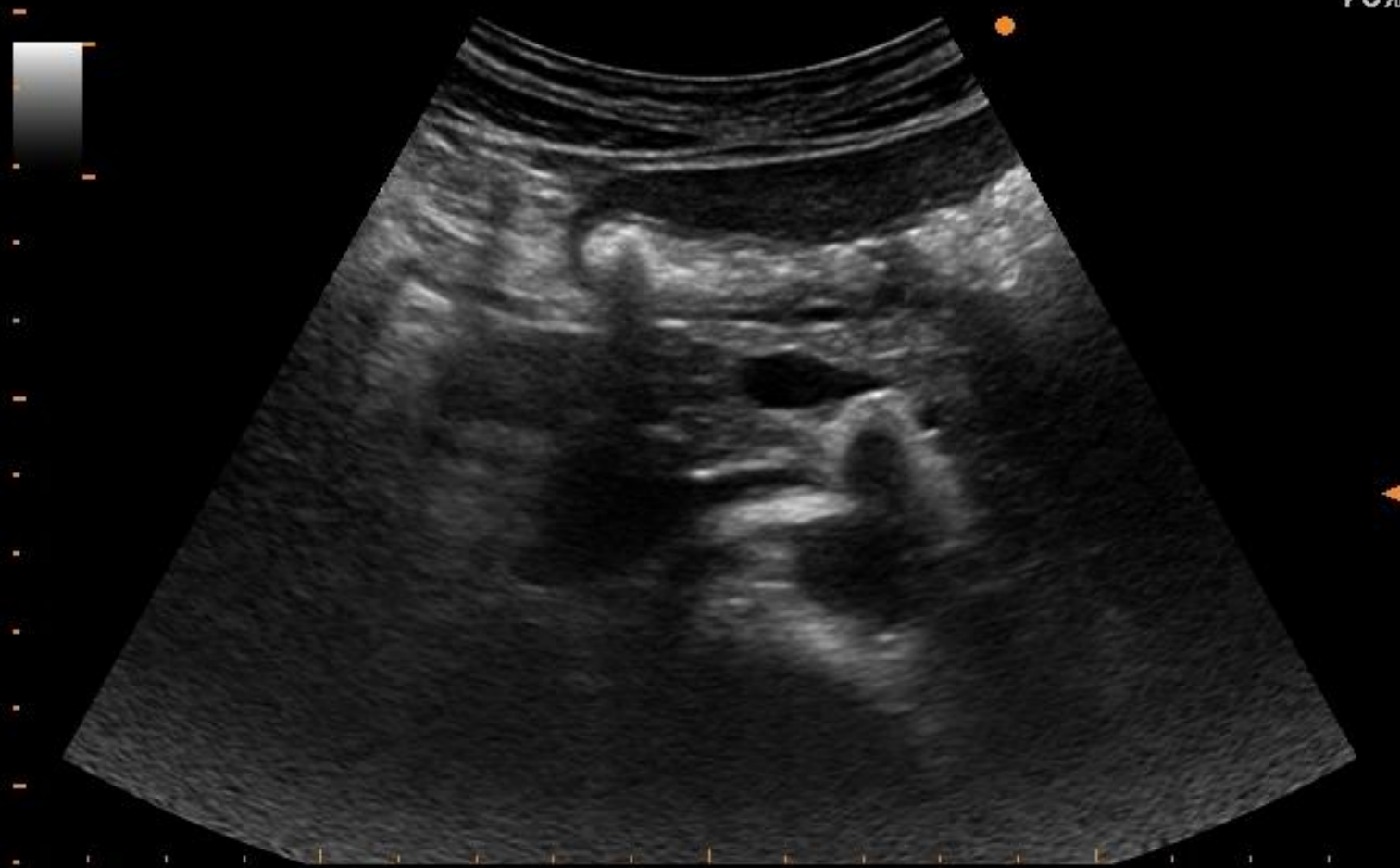
# Pancreas – Aorta/vena cava (transversaal)



ALOKA A.Z. ST- LUCAS  
GENT

15/09/22  
10:58:27

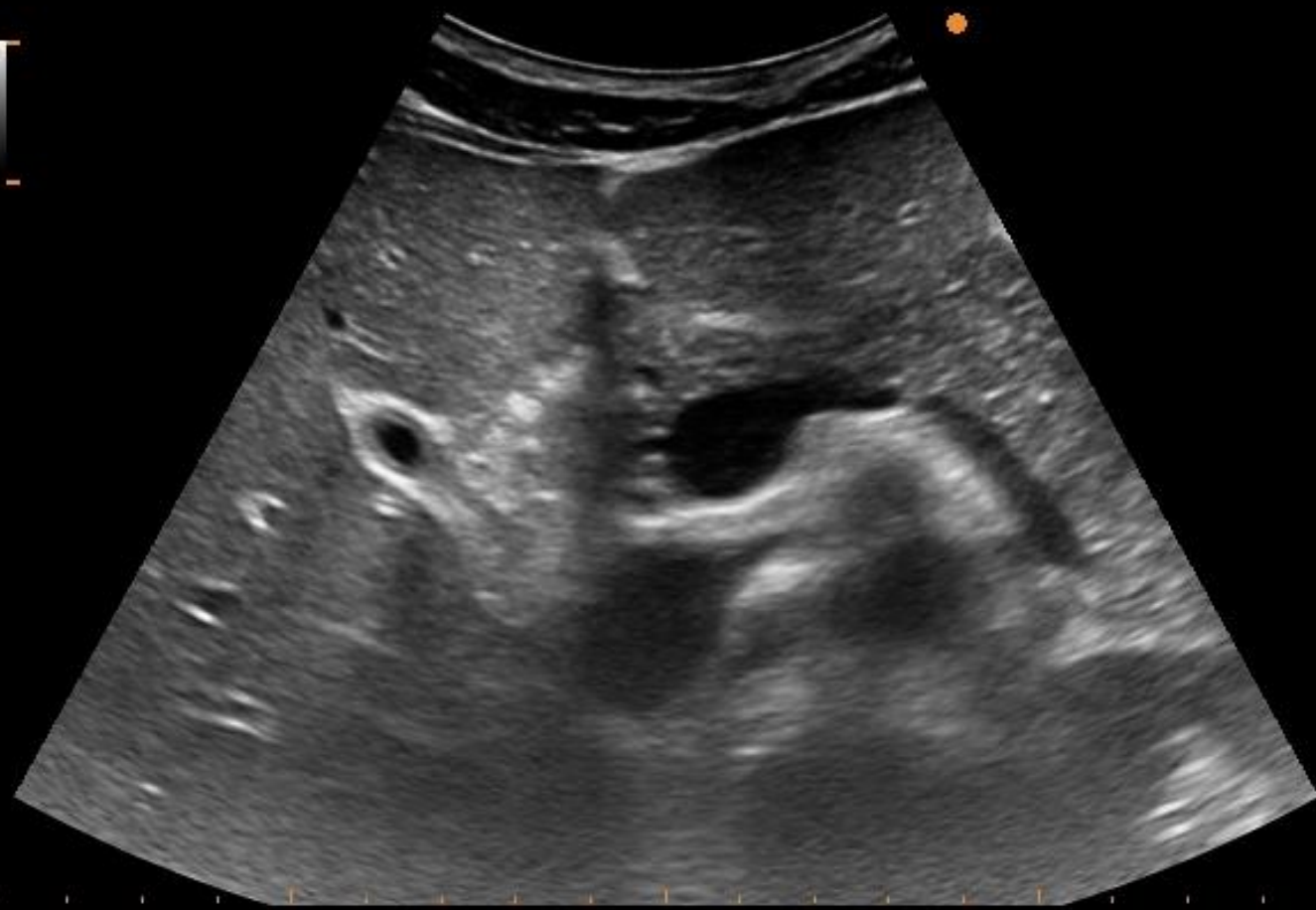
70%



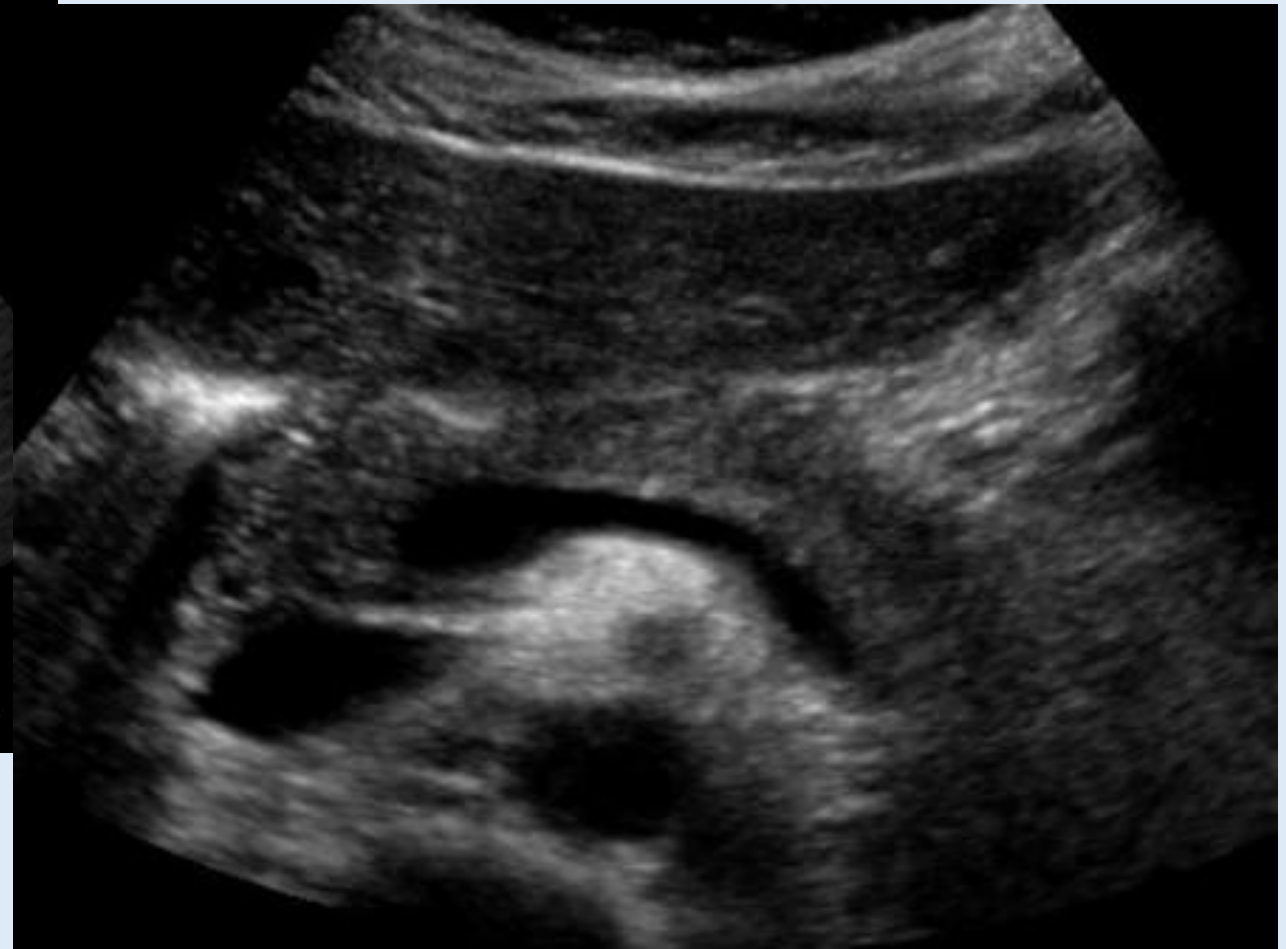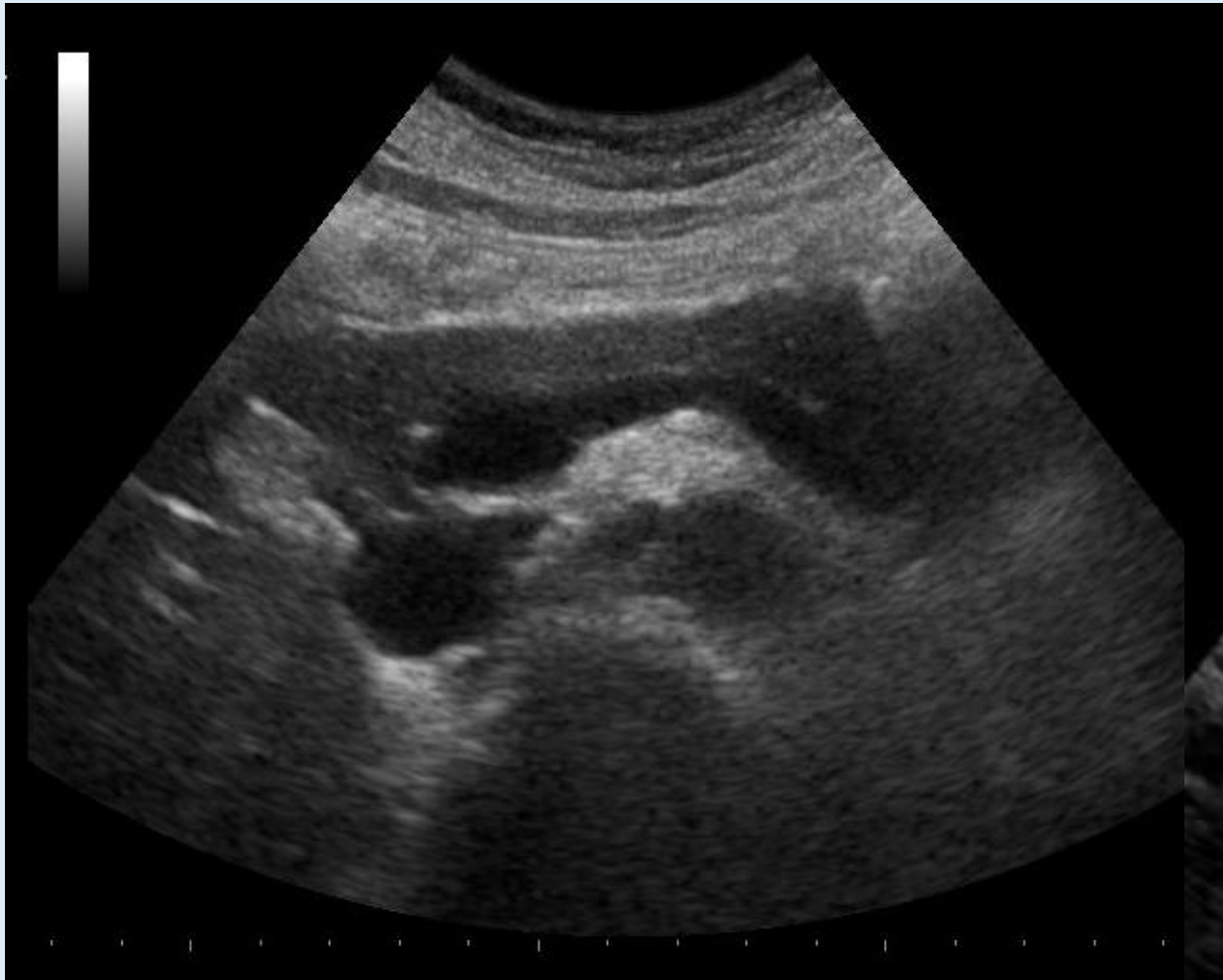ALOKA A.Z. ST- LUCAS  
GENT

15/09/22  
10:00:04

70%

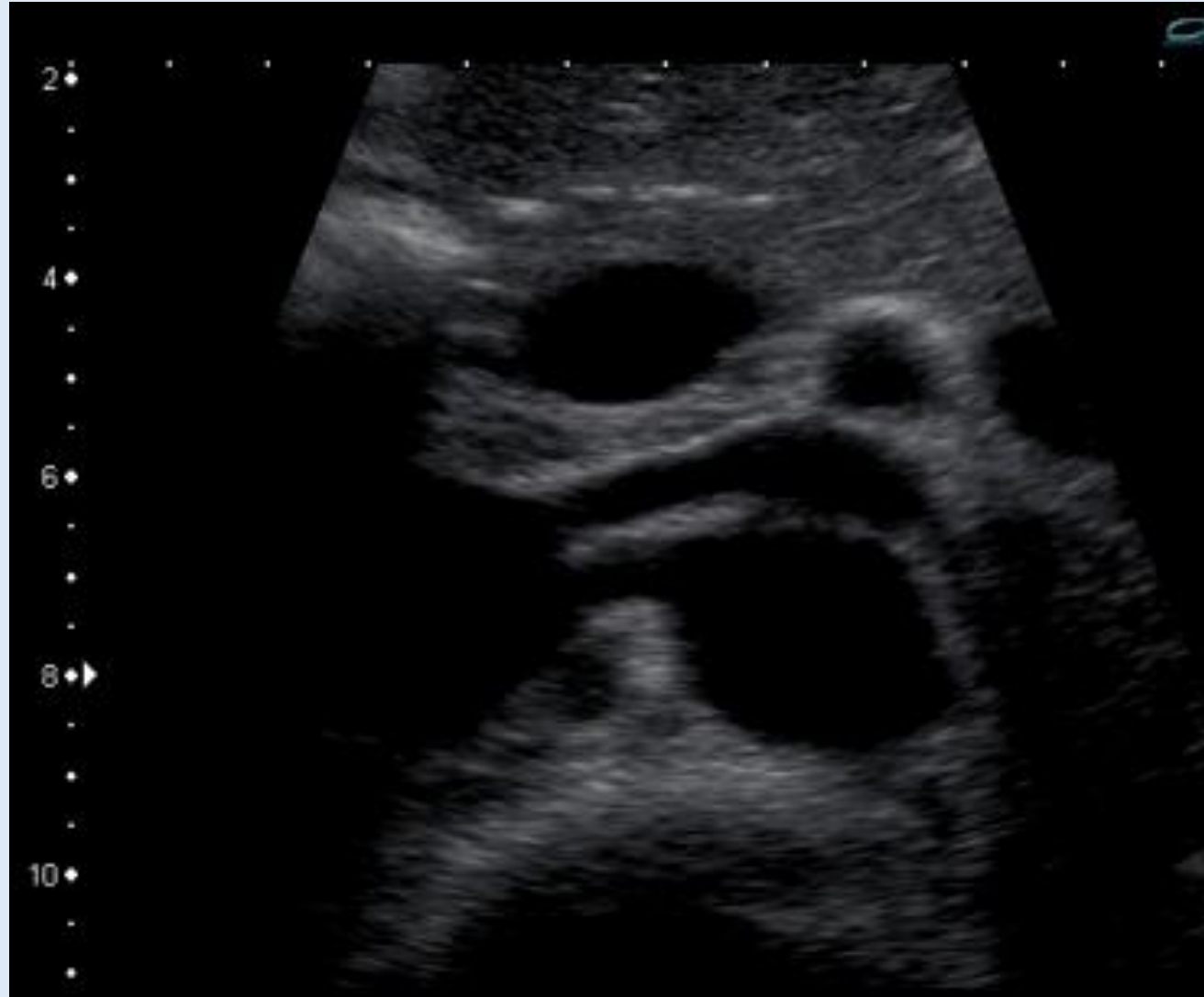

# Pancreasstaart – Aorta/vena cava (transversaal)

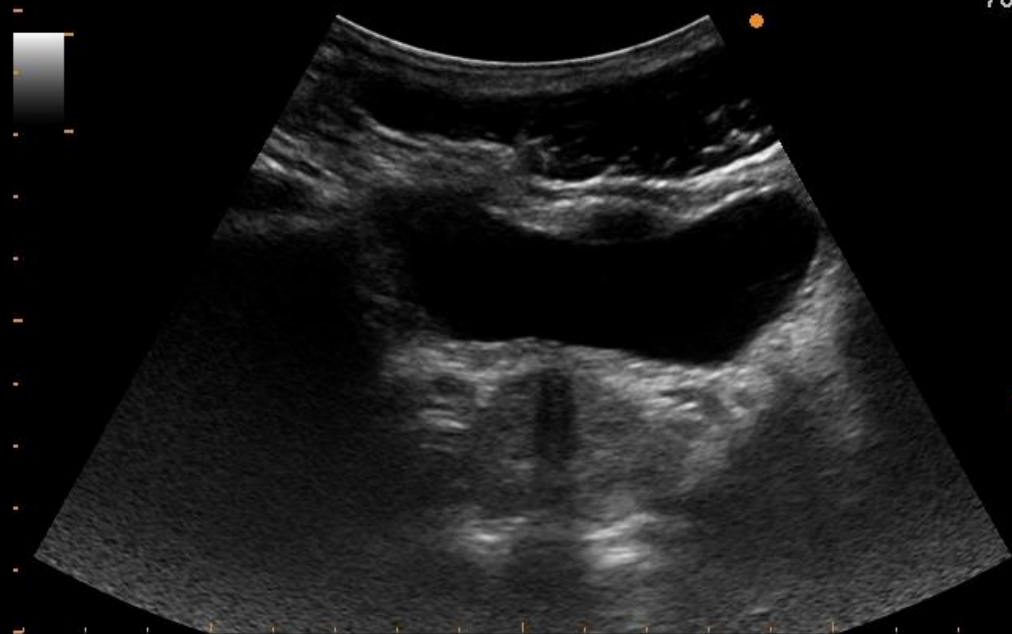




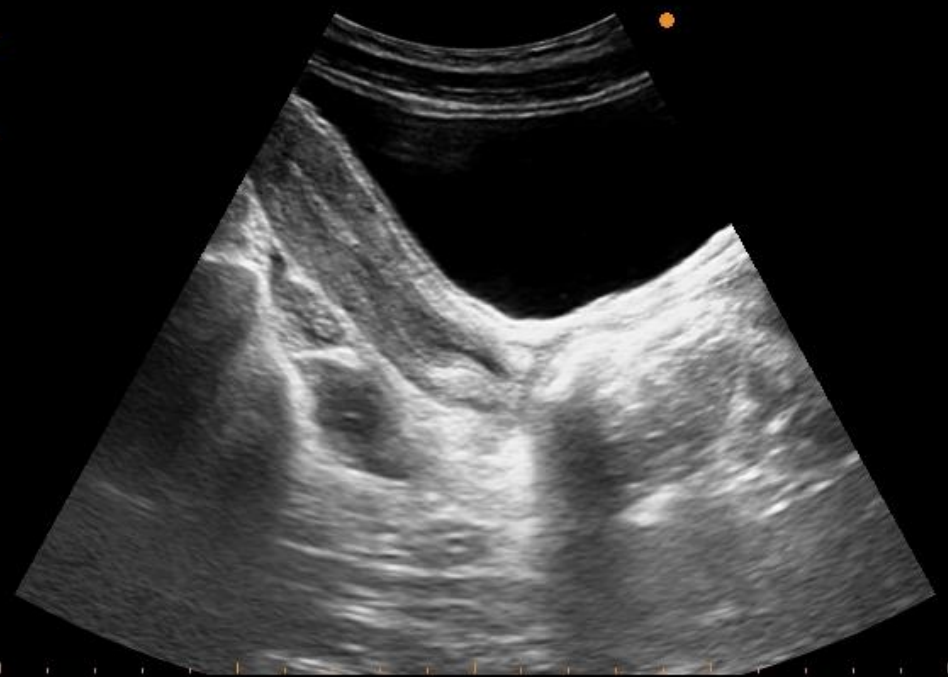# Pancreasstaart – Aorta/vena cava (transversaal)



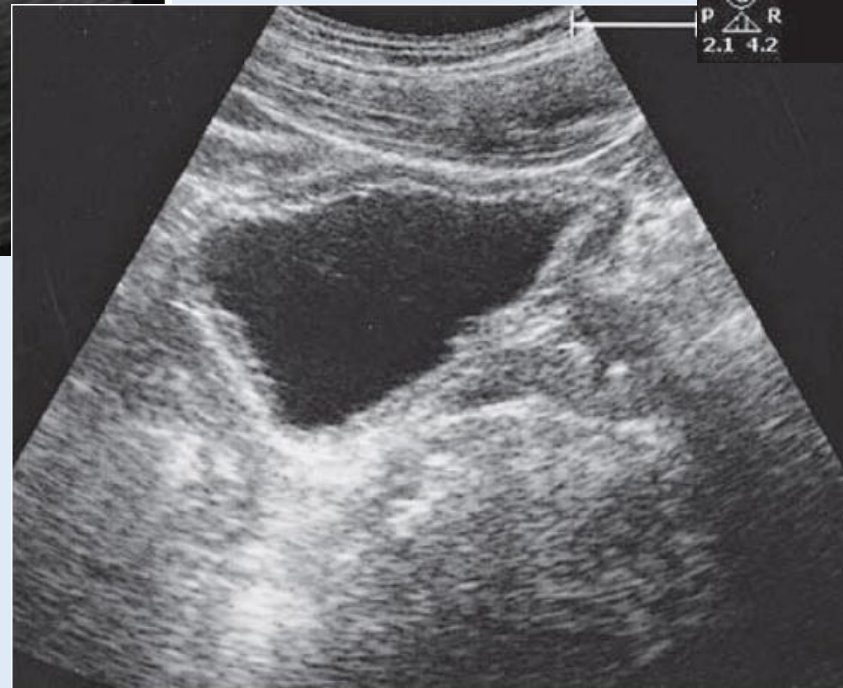
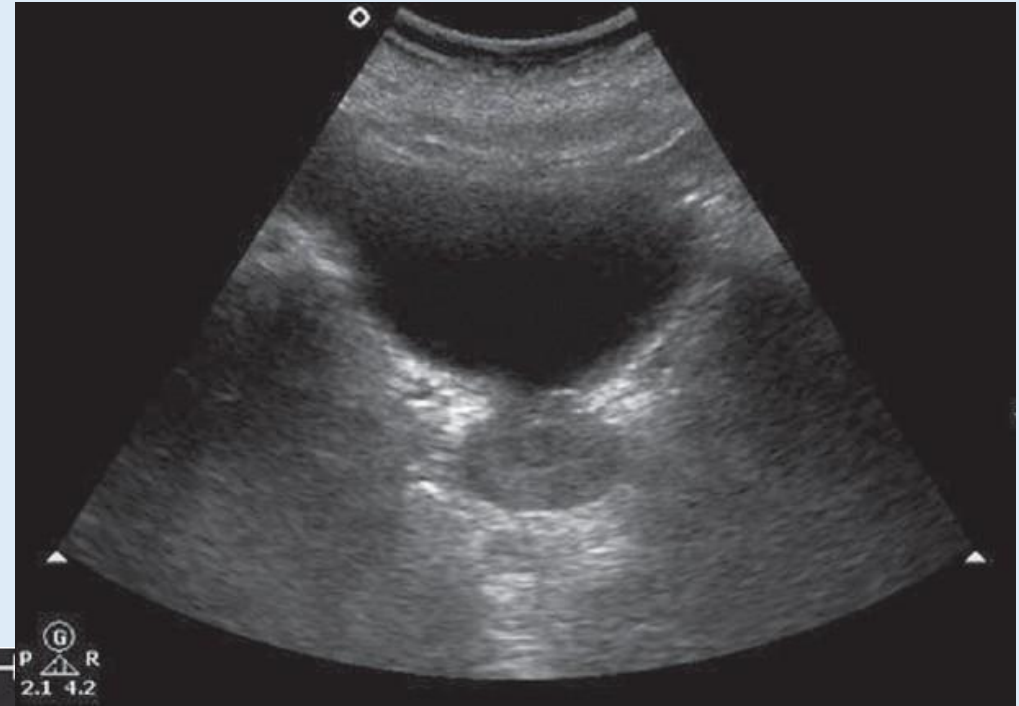
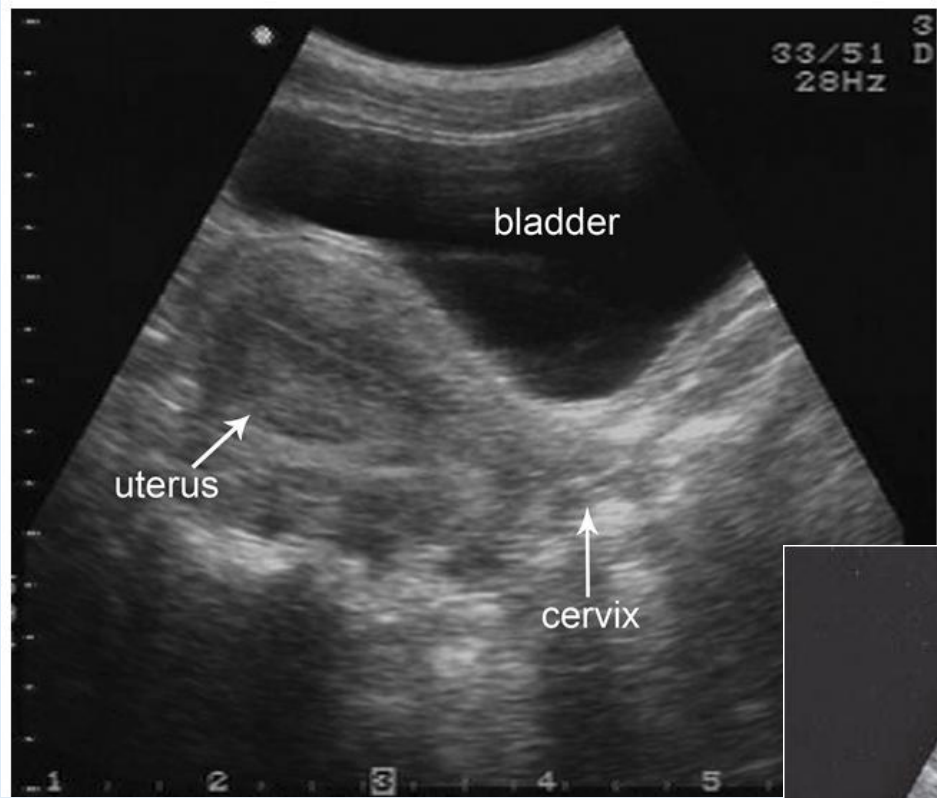
70%



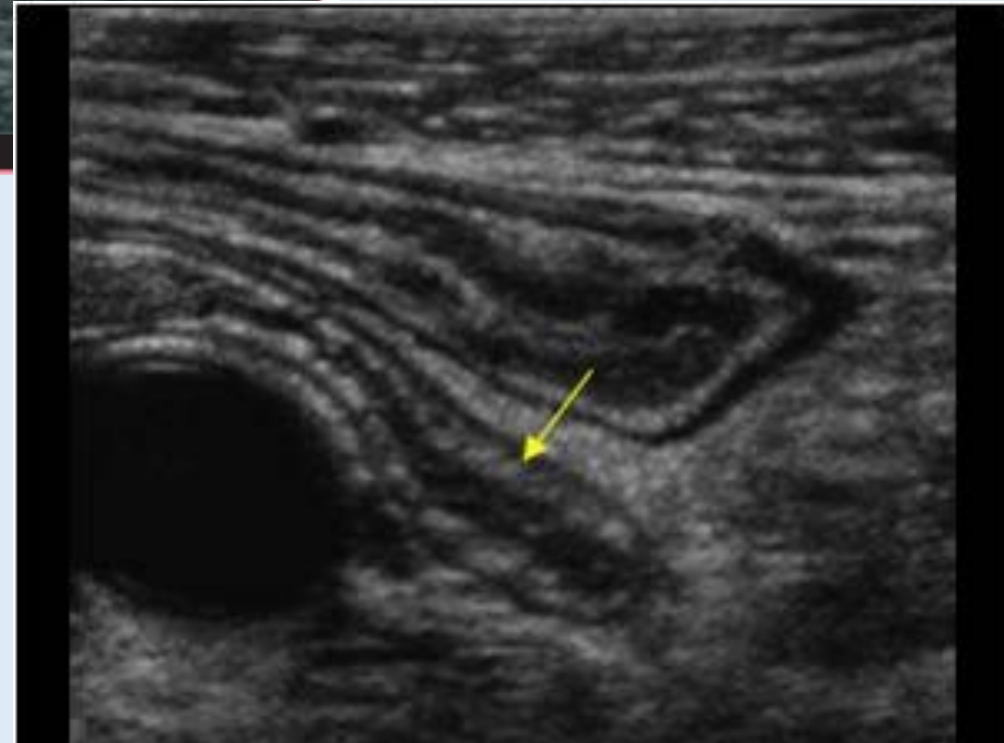
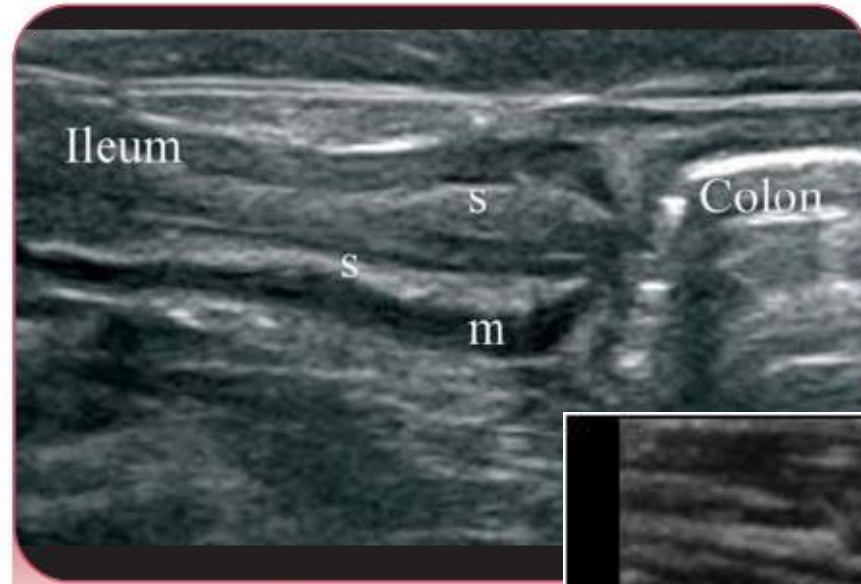
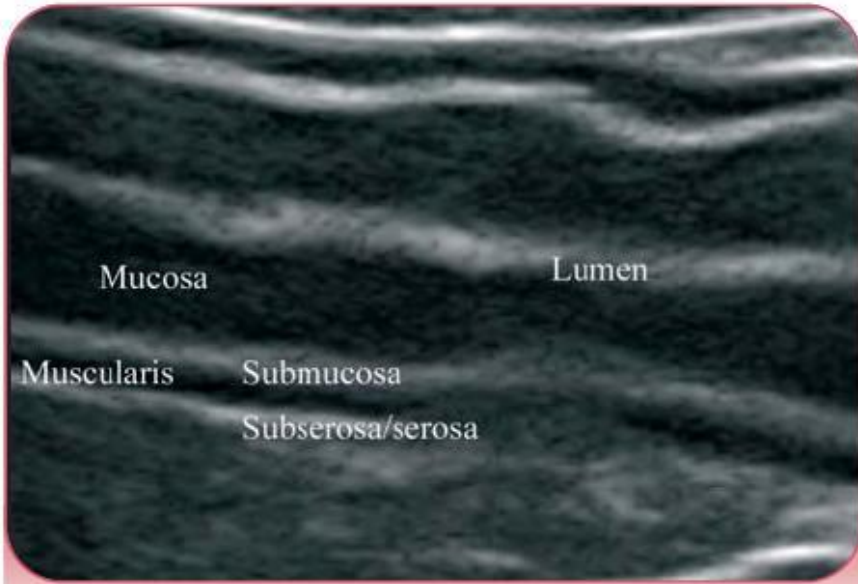
70%



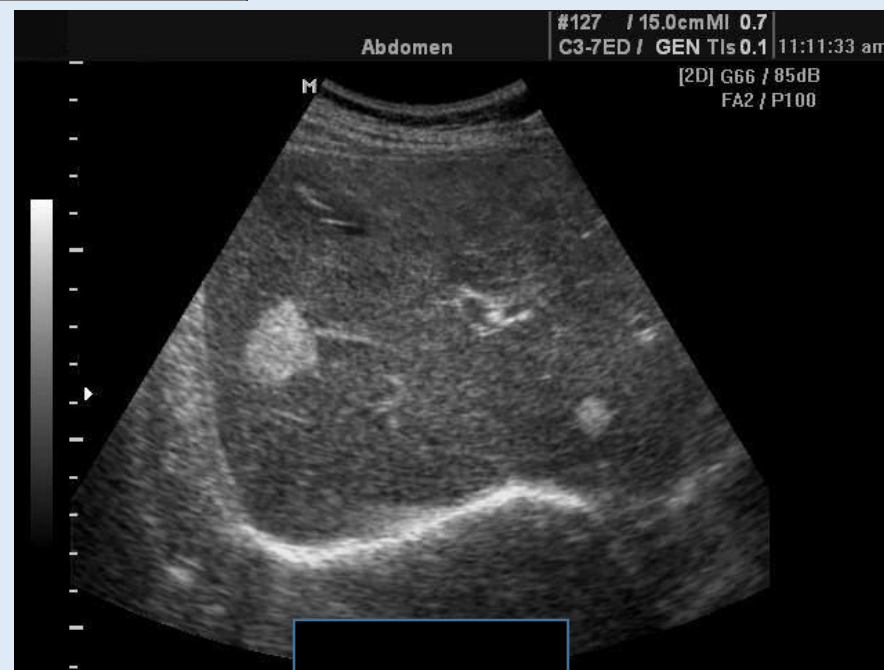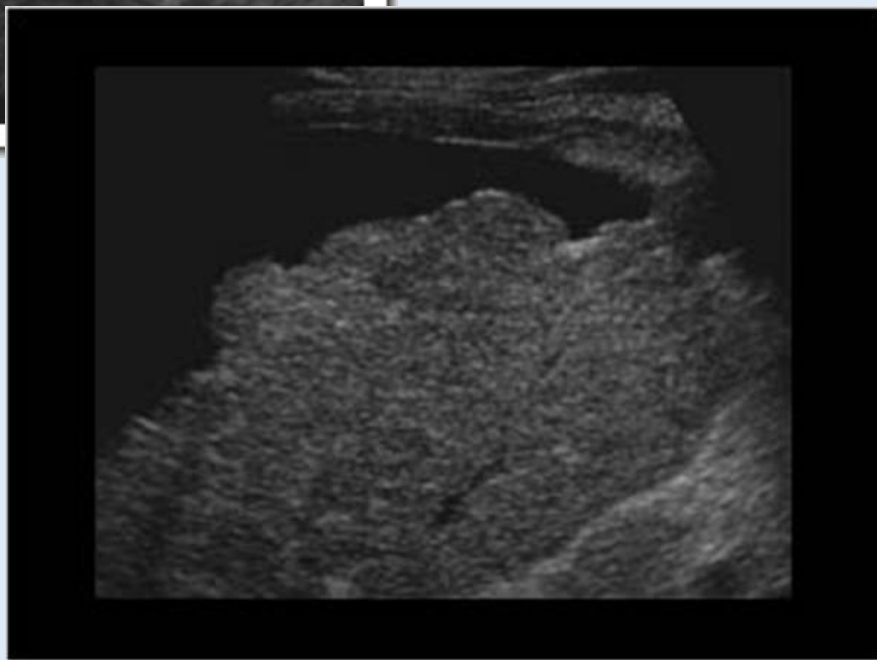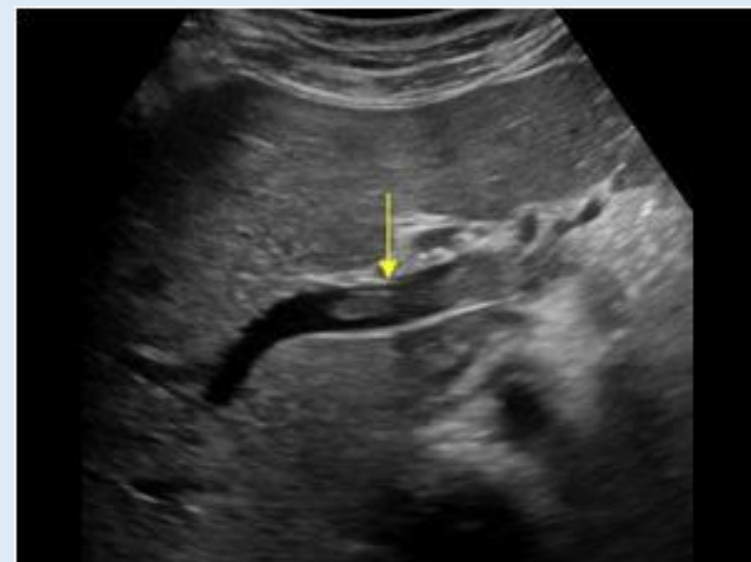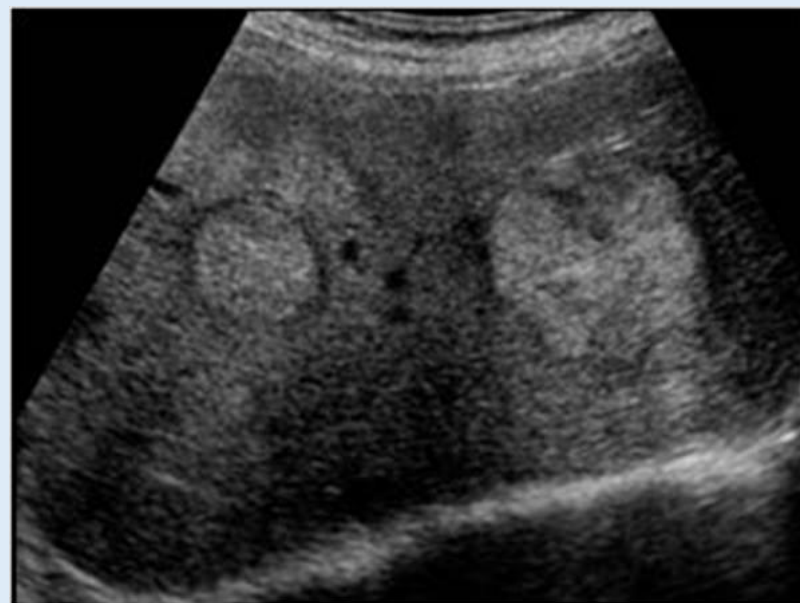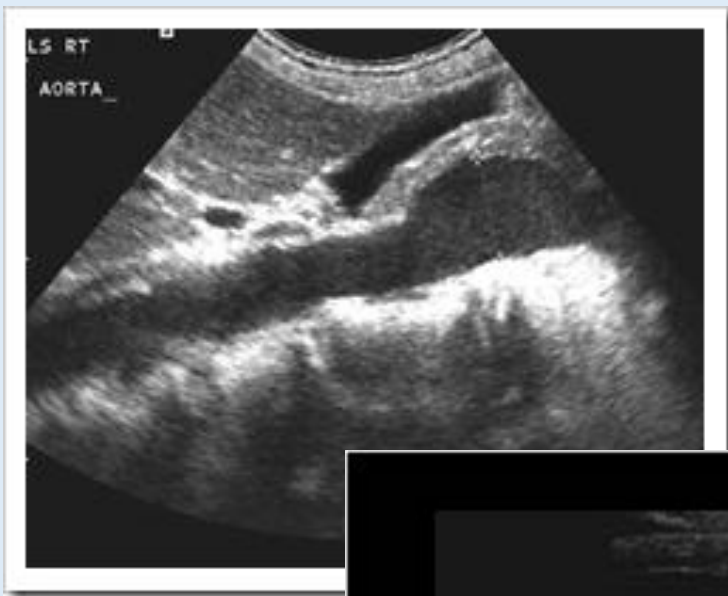# Klein bekken



# Intestinale structuren



# Pathologie



# Pathologie

